

# 8

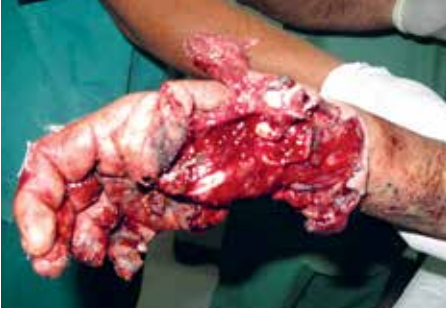## OPEN FRACTURES

---

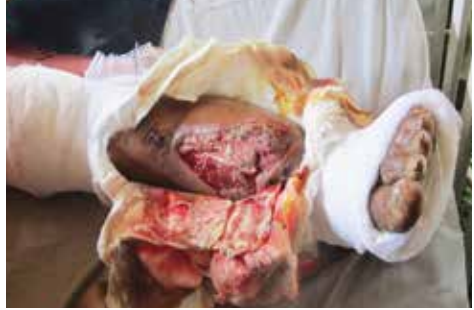SCENARIO  
WOUND DEBRIDEMENT  
FRACTURE STABILIZATION  
EXTERNAL FIXATION FOR OPEN FRACTURES  
MANAGEMENT OF OPEN FRACTURES

SUGGESTED RESOURCES

REFERENCES



(ICRC)



(Bar-On)

## SCENARIO

Your team arrived three days ago, 48 hours after the earthquake struck, and by now the hundreds of patients in the parking lot of the partly destroyed hospital have been managed, but new patients keep trickling in regularly.

A mobile surgical facility 25 kilometers away is now operational. One of the new patients is a 23-year-old female with a wound over the distal leg and exposed fracture of the tibia. There is pus in the wound but no crepitus, and the patient is febrile at 38.5° C.

**Where should this patient be managed, at a EMT type 1? EMT type 2? type 3?**



TYPE 1

- Lavage, dress, align and splint wounds
- Administer antibiotics and tetanus prophylaxis
- DO NOT CLOSE THESE WOUNDS PRIMARILY



TYPE 2

- Formal wound debridement
- Apply cast with window or external fixation for continuation of management of open wound management



TYPE 3

- Receive dressed and splinted wound from type 1 or 2 EMT.
- Provide definitive treatment with plan for long term follow up

### KEY POINT

- » Assess every patient and every injury that presents to your facility.
- » This includes removing bandages, changing dressings, and adjusting splints.
- » Every injury gets a priority and a plan!

## TRIAGE MATTERS...HAVE A PLAN

The rate at which patients present can influence the surgical plan by requiring abbreviated options. Know your situation. Patients from a SOD tend to present all at once, while the tide of patients presenting from conflicts ebbs and flows.

## DIFFERENT EXPECTATIONS

Open fractures managed in civilian practice outside of conflict zones are often caused when the bone penetrates the skin—or ‘from within.’ Limb surgeons in high-resource settings are familiar with dealing with these injuries with little contamination and a lower risk of infection than in disasters and conflict. A soft tissue injury with a break in the skin removes the biological protection of the soft tissue and of bone, opening the patient to infection of the soft tissue, the bone or both.

Open fractures in conflict are usually from the outside to in and therefore at increased risk of contamination. This is exacerbated by the contaminated surroundings and the delay in treatment initiation. Therefore, all open fractures should be assumed to be infected upon arrival.

## SPECIAL CONTEXTS

### EARTHQUAKES

Earthquakes can result in crush type injuries. These mechanisms of injury cause not only fractures but significant soft tissue injuries, which can often go unrecognized at the initial evaluation. Crush injuries should be expected in all patients with injuries caused by falling debris or entrapment under building or landslide rubble.

### FLOODS AND TSUNAMIS

Floods and tsunamis more frequently produce lacerations in large numbers, but the proportion related to fractures is reduced compared to earthquakes or conflict. Tibial fractures in floods and tsunamis are often open. Femoral fractures from tsunamis and floods are often closed.

### ARMED CONFLICT

Injuries sustained in conflict may include soft tissue injuries or open fractures. The type of injury depends on the type of weaponry used. Injuries from GSWs, blast injuries, shrapnel injuries, and landmine injuries should be expected.

## KEY POINT

- » Patients with open fractures should be considered to have a soft-tissue wound with an underlying bone injury.
- » Treatment of soft tissue injury is as important as treatment of the fracture.
- » The outcome for the patient will depend on the degree of injury of the soft tissues around the fracture.

# WOUND DEBRIDEMENT



TYPE 2

Debridement of all wounds, including open fractures should be performed by a surgeon at an EMT type 2 or 3 facility.

## Paediatric Considerations

Preserve all periosteum when possible, even if only an empty sleeve is present. Children can undergo remarkable regeneration of bone over several centimeters within a periosteal sleeve.

## WOUND DEBRIDEMENT FOR PATIENTS WITH OPEN FRACTURES

- » Washing of bone ends with a syringe of water or saline is most effective when done with a syringe with a small outlet or through a needle, rather than through a large bore outlet.
- » Each bone end must be visually inspected for contamination and cleansing.
- » Bone debridement: remove all detached, devitalized, non-articular bone fragments.
- » Leave articular fragments unless they are grossly contaminated.
- » **Avoid damaging the remaining soft tissue attachments of bone fragments.**
- » A gauze square can be used to abrade the bone ends and remove visible contaminants.
- » A dental pick is equally effective in removing material on the bone ends.
- » Use a bone nibbler or rongeur to remove the remaining contaminated ends of the fracture fragments.
- » In cases with significant bone loss, acute shortening can be performed. This will also assist in bone coverage by soft tissues.
- » Volume is more important than pressure for washout, a minimum of 3-12 L per wound is required.
- » Bones and joints should be covered by soft tissue when possible. Soft tissues should not be sutured under tension.
- » Skin should never be closed primarily.

## DIFFERENT EXPECTATIONS

While sterile isotonic solutions are used in hospitals, they are often impractical for use in a disaster setting. Clean drinking water from a tap or bottle is suitable for use washouts.

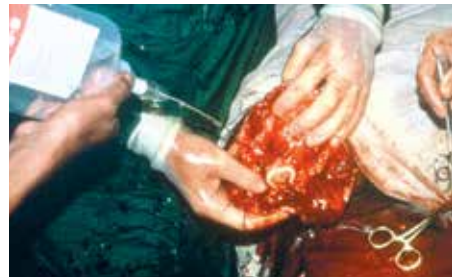

FIGURE 3 Low pressure irrigation during debridement. (ICRC)

# FRACTURE STABILIZATION

**DO NOT INTERNALLY FIX OPEN FRACTURES  
PRIMARILY IN CONFLICT RELATED WOUNDS OR  
DISASTER ENVIRONMENTS.**

## EXTERNAL FIXATION



Casting and external fixation can both provide management strategies for open fractures. In austere environments the simplest technique should always be considered first. For example, a cast with a “window” cut in the POP for wound care may be a safe and acceptable option.

External fixation of open fractures can be useful for **wound management**. However, the ease of access to wounds provided by **external fixation is not a replacement for good wound management with debridement, appropriate DPC, or other safe wound coverage**. External fixation of an open long bone fracture provides stability of the soft tissues, alignment of the fracture, protects neurovascular structures, maintains limb length, and can reduce the infection risk in comparison to longitudinal traction when used as a definitive treatment.

The goal of care of the open fracture is to provide alignment of the fracture in a stable environment for wound management and wound healing or early wound closure, in the simplest and safest way possible.

## KEY POINT

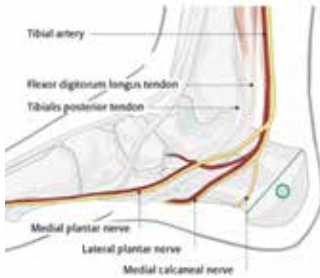- » External fixators applied initially as “temporary” may become definitive, so they should be constructed for that circumstance.
- » When applying external fixation to a femur fracture with a small distal femoral segment, the external fixation construct should span across the knee joint to the proximal tibia.

 TYPE 2	Application of external fixation is beyond the scope of a type 1 EMT and should be performed at a type 2 or 3 facility
 TYPE 3	

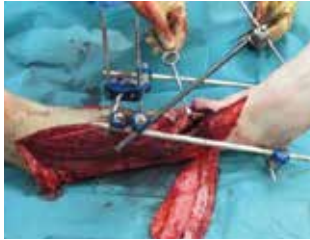
## FEMUR

If external fixation is required for fractures of the femoral shaft, fixation should include 2–3 pins above and below a fracture. The pins can be either anterior or lateral.

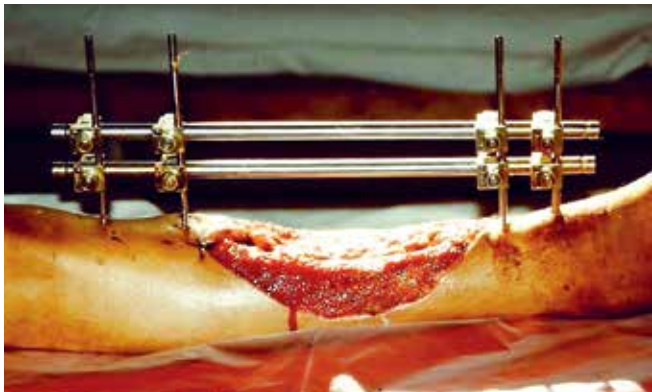
Anterior is preferred if internal fixation may follow as it avoids the surgical incision sites for internal fixation. Two pins are adequate for temporary fixation. A lateral position and three pins are preferred if it is possibly the definitive management. Do not place pins within 2 fingerbreadths of the proximal border of the patella. This will avoid placing them through the suprapatellar pouch. If needed, place the more distal pins laterally.



**Figure 4.** Insertion site for calcaneal pin.  
(AO Foundation Switzerland)



**Figure 5.** A Delta frame over an open fracture. The lateral fasciocutaneous flap has been raised to provide temporary loose immediate cover for the underlying vascular repair.(A.Kay)



**Figure 6.** Mono-axial side-tube method: the four Schanz screws are well-aligned in a row. (ICRC)

## TIBIA

A standard construct for a tibial shaft fracture should include 2–3 pins above and below a fracture on the anteromedial surface by preference, and a single bar.

More stability is provided by a second bar bridging the fracture site. This may be desirable for the management of pain related to movement at the fracture site.

## DISTAL TIBIA

Fixation should span from the proximal tibia across the ankle joint to the foot when the distal tibial segment is small, or a distal leg wound prevents pin insertion in the distal tibia.

Construct a delta frame between the tibial shaft above the fracture and the foot.

A calcaneal pin is required as well as one or more pins in the metatarsals to triangulate the frame and prevent the distal tibia and foot slipping forward or backward off the plane of the proximal tibia.

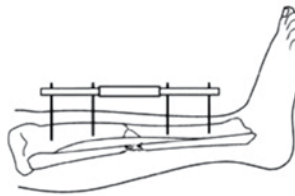
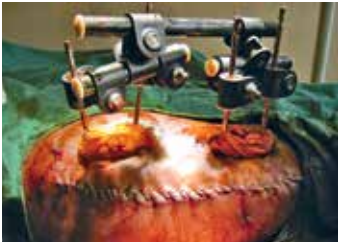## KEY POINT

- » It is important to avoid bars that are too long, impeding joint motion or extending beyond the plantar surface and impeding weight bearing.

## BIPLANAR

The pins above the fracture are connected by a short bar to create a 'handle' and the same technique used below the fracture. The fracture is reduced and the handles are then connected by a third rod.

This rod may connect the bar above to the bar below, a pin above to a pin below, or a bar one side of the fracture to a pin on the opposite side of the fracture.

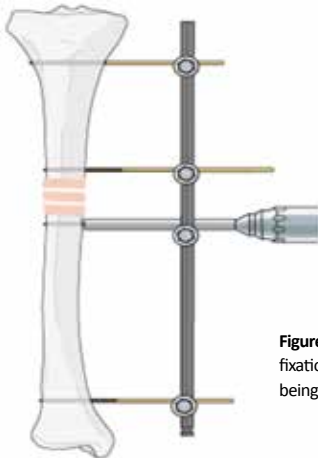


**Figure 7.** Modular technique: the two modules are manoeuvred into position, aligning the bone, both axially and rotationally, and the two short tubes joined together with a cross-tube. A second tube may then be applied to make the device more rigid. (ICRC)

## UNIPLANAR

A single pin is inserted proximally and another distally, loosely connected by a single bar.

The fracture is then reduced and the frame locked. A second pin above and another below the fracture are inserted freehand with the drill or pin resting on the bar as a guide to line up the bar and the bone.



**Figure 8.** Standard uniplanar external fixation of the tibia showing the last pin being placed distal to the fracture site.

(AO Foundation, Switzerland)

## KEY POINT

- » The further apart the pins on each side of the fracture, and the closer to the fracture the bar is, the more stable the construct. Leave room to allow for soft tissue swelling, wound care and dressing.
- » Constructs may also be attached only to the fractured bone, or span a joint.

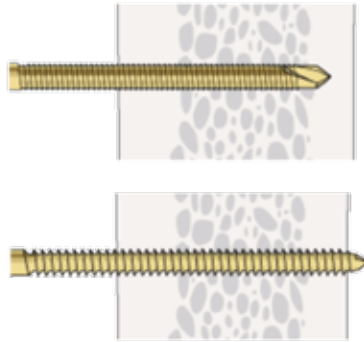
# EXTERNAL FIXATION FOR OPEN FRACTURES

## PIN SELECTION

- » Do not use conical pins—if inserted too far, they cannot be backed off without losing their fixation in bone. The re-use of threaded half pins or Shanz-type pins is not recommended due to the difficulty in cleaning, sterilizing and tracking the pins.
- » Choose threaded half pins appropriate to the size of the bone and the patient (around 1/3 of the bone diameter). **Adult lower limb: 5mm pins for almost all circumstances, and 3–4 mm in the hand and arm.**
- » Pins may be self-drilling and self-tapping, or not—check the pins. If pointed and fluted, they are self-drilling self-tapping, if round without flutes they are not.

### PAEDIATRIC CONSIDERATIONS

Children can have the same sized pins as adults from age 5. Under age 5, use 4 mm pins in the lower limb and 3 mm in the upper limb, if available.



**Figure 9.**

**A:** Self Tapping Schanz screw

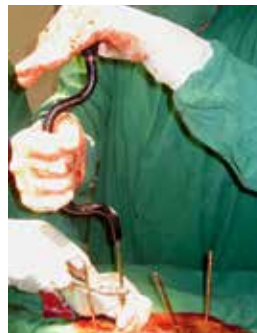**B:** Conventional threaded pin

(AO Foundation, Switzerland)

## PIN PLACEMENT

Power drills, if available should only be used by experienced surgeons. For surgeons with less orthopaedic experience, it is preferable to insert pins by hand using a Hudson brace system or a hand drill. Pre-drilling will facilitate the insertion of pins in fit, healthy people. A size 3.2 or 3.5 drill is adequate for the purpose. Self-drilling, self-tapping pins should be used when available.

If pins are not self-drilling, self-tapping, pre-drilling before pin insertion is required. Use only sharp drills. Blunt drills used on high speed produce significant heat and the heat will kill the bone in a ring around the pin.



**Figure 10.** Hand Chuck (ICRC)

**Figure 11.** Placement of a pin with a hand drill (ICRC)



## PIN SELECTION

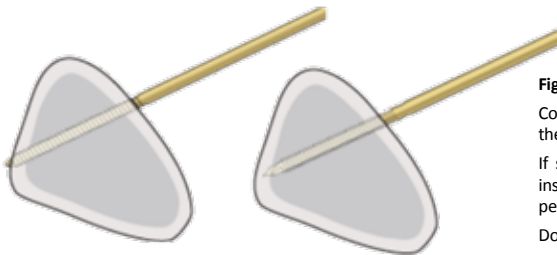
Pin length needs to be long enough to attach the connectors and allow the wearing of loose clothing but not so long that they interfere with joint movement.

The thicker the soft tissues, the longer the pin required to clear these before the blocks are added—femoral fractures need longer pins than tibial fractures.

A pin that is too short needs to be changed. A pin that is too long can be cut with bolt cutters, but this leaves a sharp end that causes the patient difficulty with protecting themselves, their clothing and bedding from injury.

Pins can be inserted under local anaesthesia, 5mL of lidocaine 1% on each side, from the skin down to the bone, as the periosteum is richly innervated.

Wait 5 minutes for the local to take effect, and make generous longitudinal skin incisions (at least 1 cm, not just a knife stab) so there will be no tension on the skin from the pin after the construct is secured. When inserting the pin, “walk” it on the bone to feel the anterior and posterior cortices, and triangulate to feel the mid-portion of the bone, where the pin should be inserted.



**Figure 12.**

Correct depth insertion may be achieved by feeling the opposite cortex.

If self-drilling screws are used (far left), they are inserted through the near cortex until they just penetrate the far cortex.

Do not break through the far cortex.

(AO Foundation, Switzerland)

## KEY POINT

- » **Ring Sequestra:** Drilling by hand limits the drill speed, and therefore heat generation. It will quickly be recognized if a blunt drill is in use. If using a power drill, ensure every drill bit is sharp to reduce heat generation and the risk of ring sequestra. These ring sequestra harbor infection when a pin site becomes infected and can become the source of osteomyelitis and continuous discharge of pus.
- » **Pin Length:** Check the two pins for each bone segment before you insert the first. The second pin will give you a guide as to how much of the pin is engaged in the bone—or projecting beyond the far side of the bone.

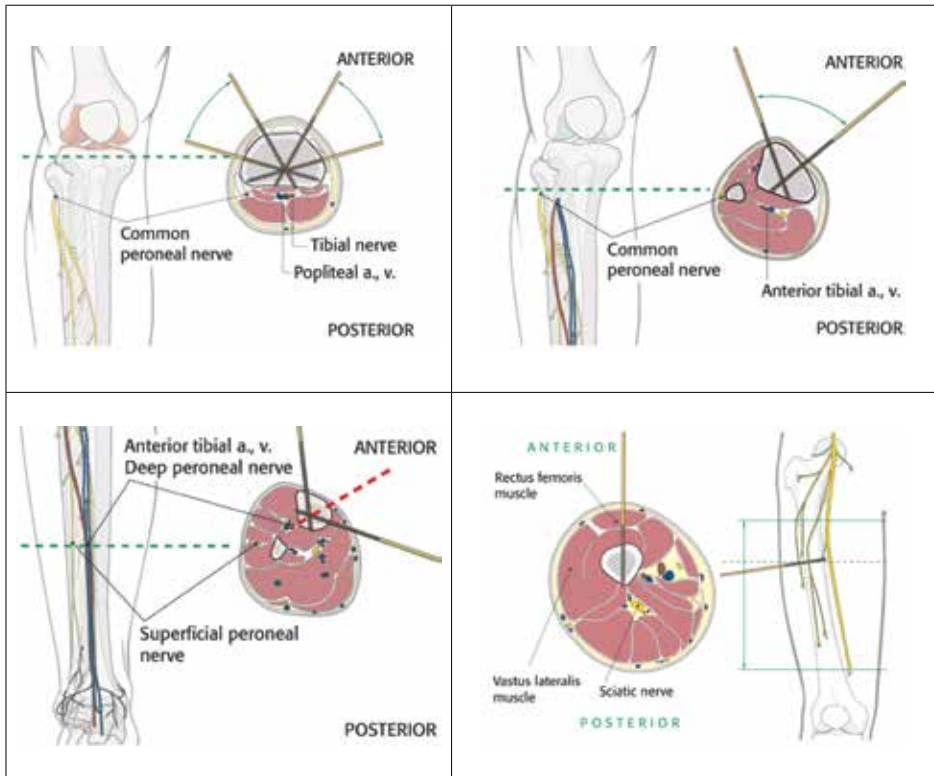
## SELECTION OF PIN ENTRY POINT

Pins should preferably be inserted separate from the wound, rather than through the wound. Pins placed through the wound may cause further soft tissue damage and interfere with wound care and coverage.

All pin sites are considered contaminated and some become frankly infected.

Consider the surgical approach for any future internal fixation or soft tissue reconstruction and avoid placing pins in this line. Internal fixation is an unlikely option following an open fracture and would only be considered after the wound has healed.

Consider also what structures are at risk on entry and at the exit point on the far side of the bone. Safe zones are described to assist in pin placement in the tibia.



**Figure 13.** Safe zones for access to the proximal tibia  
(AO Foundation, Switzerland)

## PIN DEPTH

Pins are often inserted in disaster response and conflict environments without the benefit of radiological control.

Depth of pin insertion is important as a pin inserted too deeply can damage structures on the far side of the bone. Correction of an overly deep pin requires anaesthesia. Correct depth at the time of first insertion is desirable. It is far easier to judge pin depth when the pin is inserted **by hand**.

**Tibial pin depth** can be estimated from the breadth of the subcutaneous border of the tibia. The tibia is roughly triangular.

The depth of insertion should approximate the palpable bone breadth. With one pin on the bone, a second pin of equal length put on the skin will give you an idea of how much further you need to go.

As the pin engages the far cortex, it becomes more difficult to turn.

***Three and a half full turns from this point should have the pin fully engaged in the far cortex***, but not projecting beyond it by more than a few millimetres.

If using a power tool drill to insert pins, imaging would ideally be obtained to check depth whilst the patient is anaesthetized.

### PITFALL

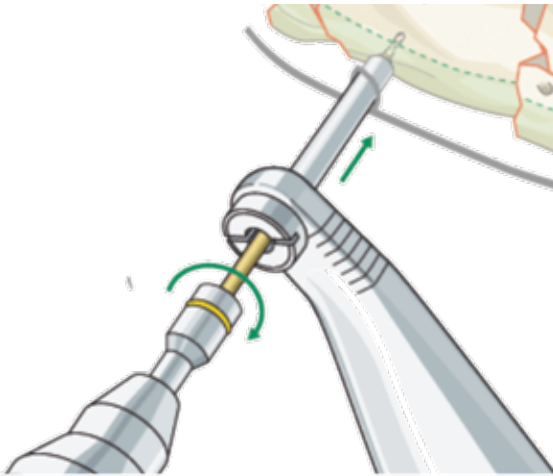
#### FAILING TO CHECK THE NEUROVASCULAR STATUS AFTER PIN INSERTION

**Always check the neurovascular status of the limb after the patient has recovered from the anesthetic and record this in the clinical notes.**

**Ensure that there has been no deterioration compared to the patient's pre-operative exam.**

## KEYS TO PLACEMENT OF EXTERNAL FIXATION

- » The closer pins are to a fracture, the more stable the construct.
- » The further apart pins are on each side of the fracture, the more stable the construct.
- » Two pins a set distance apart have a higher pull out strength the more distant they are from the fracture.
- » The closer the frame is to the bone, the more stable the construct. Keep the frame as low as possible within the limits of needing to tend to the wound.
- » Inserting pins through a block provided in some external fixation systems requires that the pins be perfectly parallel and a set distance apart. Use the block and any tissue protectors as the guide to perfect pin placement.
- » If inserting pins as individual pins, they do not need to be at right angles to the bone. Angling them apart may better suit the construction of a handle, and avoid insertion of the tip of the pin into a joint or the fracture site.



**Figure 14.** Image demonstrating the use of a soft tissue protection guide for the protection of soft tissue superficial to pin placement site  
(AO Foundation, Switzerland)

### KEY POINT

- » Always use a soft tissue protection guide when drilling or inserting pins. This prevents winding up neurovascular tissues on the drill or pin.

## SAFE ZONES OF THE FEMUR

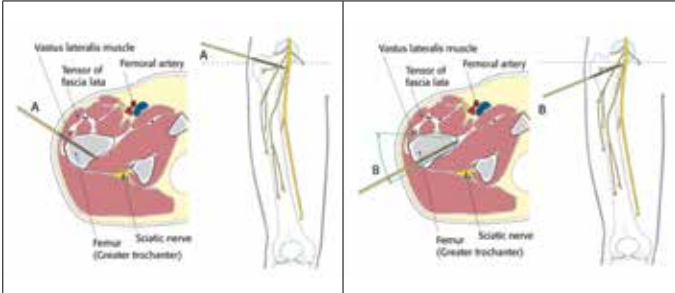


Figure 15A

Figure 15B

(AO Foundation, Switzerland)

### Proximal 1/3

With the patient supine, the greater trochanter is palpated and, depending on the fracture configuration, the pin is directed through the vastus lateralis, either aiming towards the lesser trochanter (15A) or the femoral neck (15B).

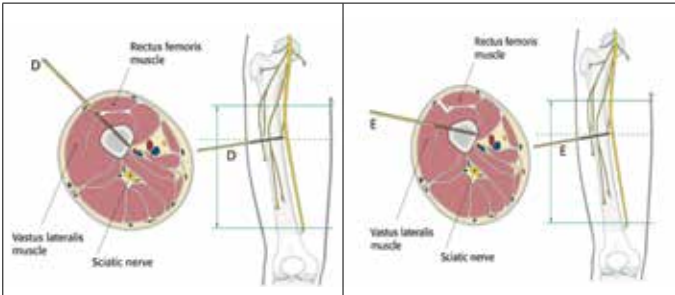


Figure 16D

Figure 16E

(AO Foundation, Switzerland)

### Midshaft

**Anterolateral Approach (Figure 16D)** Vastus lateralis and rectus femoris are palpated with the patient in supine position. The direction of the pin should be in the plane between these two muscles. The **Direct Lateral Approach (16E)**.

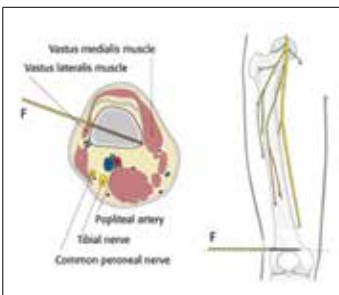


Figure 17F

(AO Foundation, Switzerland)

### Distal 1/3

**Direct lateral approach (17F)** The lateral area of the distal part of the femur is easily accessible for pin insertion. The distal part of vastus lateralis is the only structure of the soft-tissue envelope to consider. The direction of the pin should follow path (F).

## KEY POINT

- » Posterolateral pin insertion is possible but should be avoided as it places the sciatic nerve at risk and so that the external fixator frame does not interfere with sitting or lying supine.

## Proximal

### Neurovascular structures (NVS)

In the depth of the popliteal fossa we find the neurovascular structures in close proximity to the bone. The exact distance of the neurovascular structures to the bone and to the middle of the tibia is variable.

### Knee joint capsule

Pin placement should respect the knee joint capsule and therefore be below 2 cm of the tibial plateau. If a more proximal pin fixation is necessary for very high fractures, pin placement should be as anterior as possible due to the shorter extent of the knee joint capsule in this area. (Figure 18)

## Tibiofibular joint

### Transfixation

At the level of the fibular head the only safe zones for transfixation of the tibia are the medial and lateral zones.

### Unilateral fixation

At the level of the fibular head both sides of the patellar ligament are a safe zone for unilateral frame fixation. Therefore, one can construct a T-frame with good stability with only a minor risk of intra-articular pin placement. (Figure 19)

## Distal to tibial tuberosity

To minimize the risk of infection, it is best to insert the pins where soft-tissue coverage is minimal. Therefore, distal to the tibial tubercle the safe zones for pin insertion are the tibial crest and the medial face of the tibia. One must be careful and avoid deep penetration beyond the far cortex. (Figure 20)

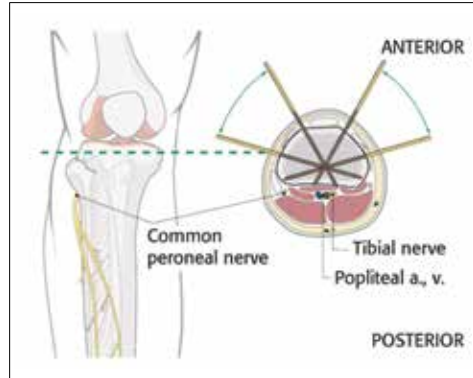


Figure 18

(AO Foundation, Switzerland)

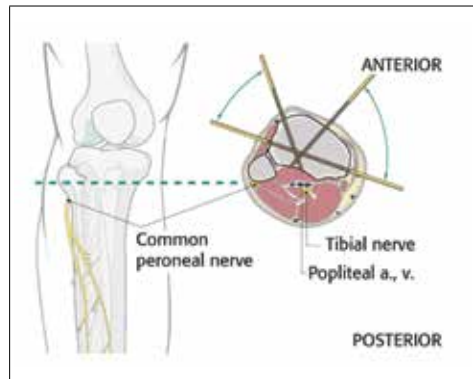


Figure 19

(AO Foundation, Switzerland)

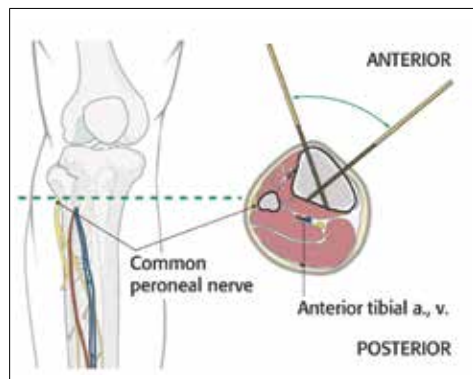


Figure 20

(AO Foundation, Switzerland)

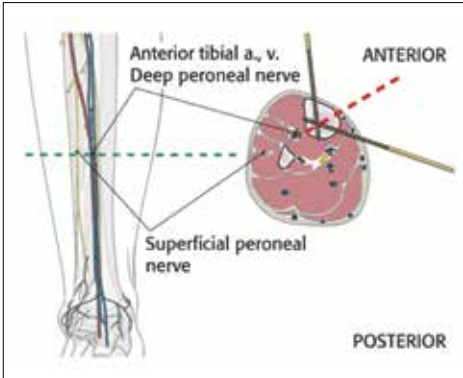


Figure 21

(AO Foundation, Switzerland)

### Tibial shaft

The neurovascular bundle (the anterior tibial artery and vein together with the deep peroneal nerve) run anterior to the interosseous membrane close to the posterolateral border of the tibia.

They are at risk if the pin is inserted in the direction as indicated by the red dotted line approximately half way between the anterior crest and the medial edge of the tibia. (Figure 21)

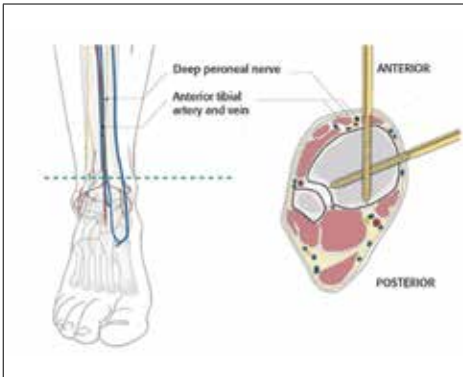


Figure 22

(AO Foundation, Switzerland)

### Tibiofibular joint

When inserting Schanz screws in the distal zone take into account the position of the anterior tibial artery and vein.

Percutaneous insertion of Schanz screws in this area is dangerous. A minimal incision will allow preparation and safe insertion. (Figure 22)

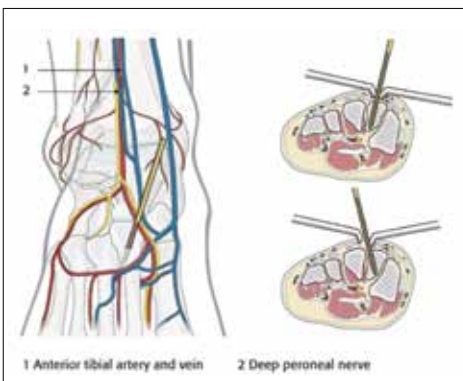


Figure 23

(AO Foundation, Switzerland)

### Metatarsal placement

A small Schanz screw (4 mm) can be placed in the second metatarsal.

However, remember that the dorsalis pedis artery and veins and deep peroneal nerve lie on the medial side of the second metatarsal base.

A pin inserted here requires blunt dissection to the bone and careful retraction.

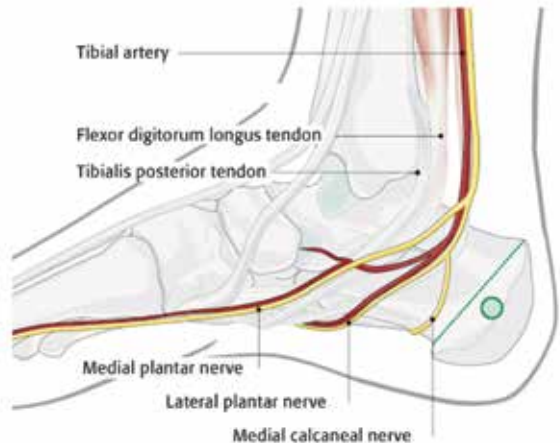
## PLACEMENT OF CALCANEAL PINS

Use a full length Denham pin. This looks like a Steinman pin but has a central threaded section to prevent slippage in the bone.

A Steinman pin can be used, but will have a reduced period of effectiveness until it starts to slip in the bone. Place this pin 2/3 of the way along a line between the tip of the medial malleolus and the tip of the heel. The neurovascular bundle is 1/3 of the way down this line. The neurovascular bundle is nearer the medial malleolus. Insert the calcaneal pin from the medial side to reduce the risk of inadvertently impaling the neurovascular bundle. Ensure that the pin is inserted in plane 90 degrees to the long axis of the tibia.

### PAEDIATRIC CONSIDERATIONS

- » External fixation pins in children with open growth plates should be inserted in the metaphysis, 1 cm from the growth plate. The growth plate and epiphysis should be avoided in order to prevent iatrogenic growth disturbances.
- » Remember that the anterior proximal tibial growth plate extends into the tibial tuberosity.
- » **As a rough guide, the long bones in boys cease growth around 16 years of age and girls around 14 years of age. However, delayed onset of menarche due to being underweight or having poor nutrition will prolong the years of growth in girls.**

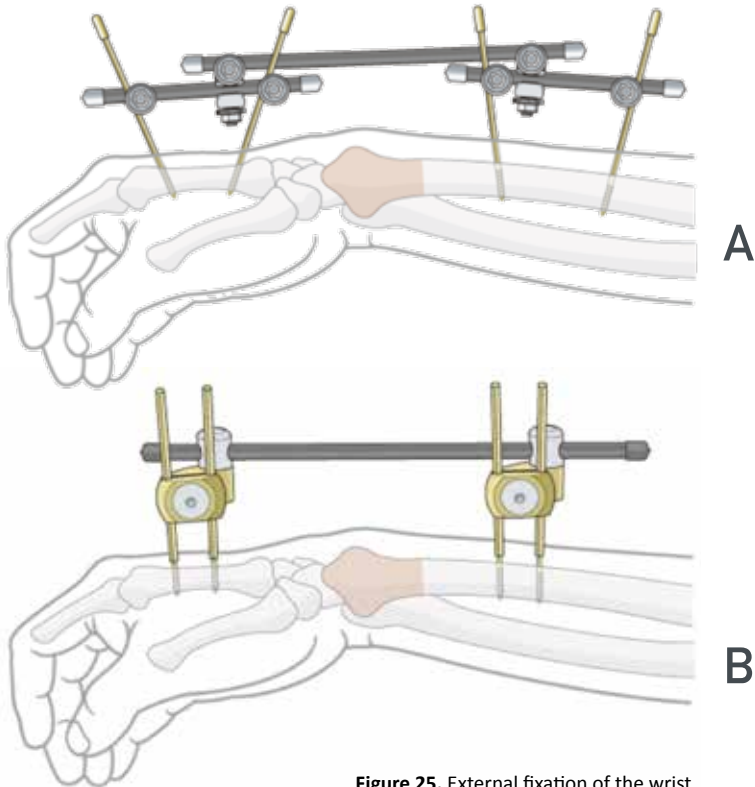


**Figure 24.** Calcaneal pin placement site. (AO Foundation, Switzerland)



## TECHNIQUE FOR BRIDGING THE WRIST

- » Forearm pins—4 mm pins x 2 in the radius, placed under direct vision, avoiding the dorsal branch of the radial nerve
- » 3 mm pins in the 2nd or 3rd metacarpal dorsally, ensuring the extensor tendons are not impaled or wound up on the pins.
- » Construct a handle on the forearm, and a second handle on the metacarpal and connect the 2 handles with a 3rd bar. (Figure 25A)
- » Alternatively the technique using a single pin proximally and distally can be implemented, and the additional 2 pins can be added after reduction. (Figure 25B)



**Figure 25.** External fixation of the wrist  
(AO Foundation, Switzerland)

## PIN CARE

- » All management techniques are intended to prevent the bone or tissues around the pins from becoming infected.
- » Absorbent dressings to soak up early oozing of blood are usually applied in the operating room at the time of insertion. This discharge usually stops at 24–48 hours.
- » A dry square of sponge with a small ‘L’ cut into it fits neatly around the pin, soaks up tissue fluid and is easily removed at 48 hours. No additional support to keep it in place is needed, but dressings for the limb wounds can be easily applied over top of the L-cut sponges.
- » Dressing pin sites, with gels, ointments, or occlusive dressings should be avoided as they will prevent drainage from around the pin sites. Erring on the side of a slightly larger incisions during pin placement can aid with drainage.
- » After 48 hours, the absorbent pin dressing can be removed. Care from this may be dictated by the local infrastructure and accessibility of available medical care.
- » Daily routines of pin washing and removing of crusts by the patient are often advised, and the patient may be permitted to shower or bathe and dry the pin sites afterwards. The washing of pin sites should be done using a safe water supply.
- » The skin around the pin should be mobilized daily to prevent the skin from "closing" on the pin.
- » Pin site infections if caught early can be managed by a short course of antibiotics. However, persistent infection should be treated by IV antibiotics, local debridement or pin change in order to prevent deep infection and chronic osteomyelitis.
- » Established infection results in pin loosening. If the fracture is not united this may necessitate re-siting the pin and reconstructing a frame.
- » Once the wound over an open tibial fracture is healed and stable, the external fixator can be replaced by a cast (usually around 6 weeks following the fracture).
- » In remote and rural areas, where clean water is a finite resource and preserved for drinking, external fixation pins are often covered in swathes of bandages in an effort to prevent dust getting into the tissues alongside the pins.

# MANAGEMENT OF OPEN FRACTURES

## H

### TYPE 3

Treatment of long segment defects requires long term follow up and should be sent to a type 3 if possible.

## SEGMENTAL DEFECTS IN LONG BONES

- » In the event of loss of a segment of a long bone shaft of <5cm, consider an acute shortening to allow the bone ends to contact and facilitate primary union.
- » Later lengthening may be an option.
- » An alternative if swelling is already a problem is to apply an external fixator with the bone segment at the normal length to rest the soft tissues and make a plan to acutely shorten the segment when the swelling resolves and the risk of compartment syndrome has been minimized.
- » Segmental loss of greater than 5 cm, particularly if associated with significant soft tissue damage and nerve injury (mangled extremity) often results in poor functional outcomes. Early amputation could be considered based on the soft tissue injury.

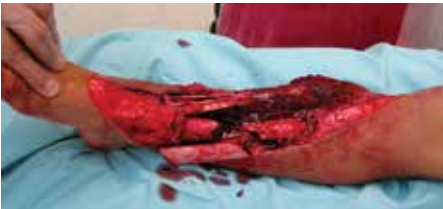

Figure 26. Open tibial fracture with non-viable bone and soft tissue loss. (Bar-On)

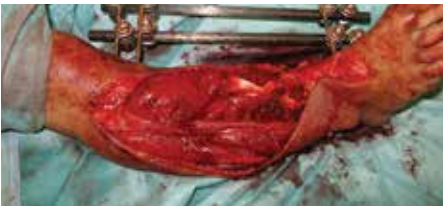

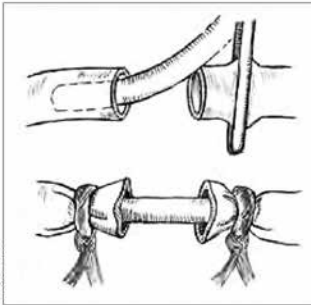
Figure 27. Fracture from Fig. 26 following extensive bone and soft tissue debridement, shortening and external fixation. (Bar-On)

## CONTROVERSY!

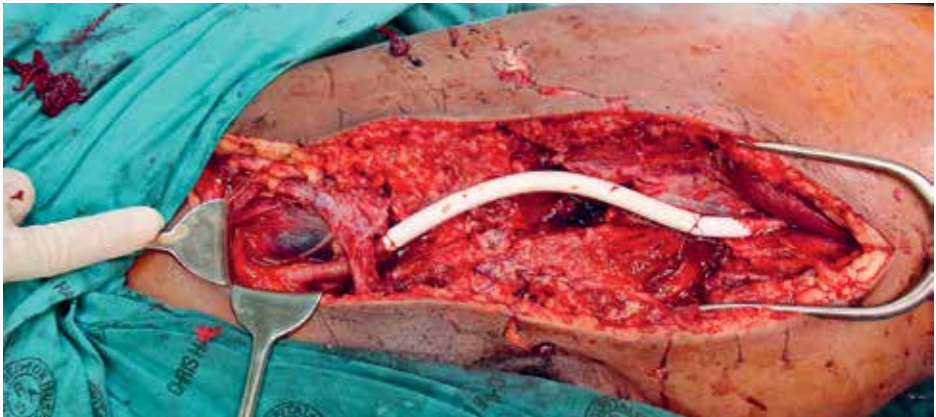
In the event of open fracture with interruption of vascular supply vascular shunting (see next page) should be a standard skill. However, the duration of shunting remains an open question without consensus.

## OPEN FRACTURES WITH VASCULAR INJURY

- » The return of circulation to distal tissues is time critical. Warm ischaemic time should not exceed 4 hours.
- » Some bone stabilization is required if any vascular reconstruction or repair is performed. External fixation would be the most likely preferred option.
- » If time permits, then external fixation prior to vascular repair prevents bone movement during pin insertion and fracture reduction from stressing the vascular repair.
- » For this approach to be effective, patients must be able to be evacuated promptly to a higher level of care.
- » If the limb is viable, shunt with a longer than required shunt, then apply an external fixator and perform a distal fasciotomy.
- » Convert the shunt to vascular repair at a suitable time. If formal vascular shunts are not available, any tube of appropriate size will do (IV or paediatric nasogastric tubing).



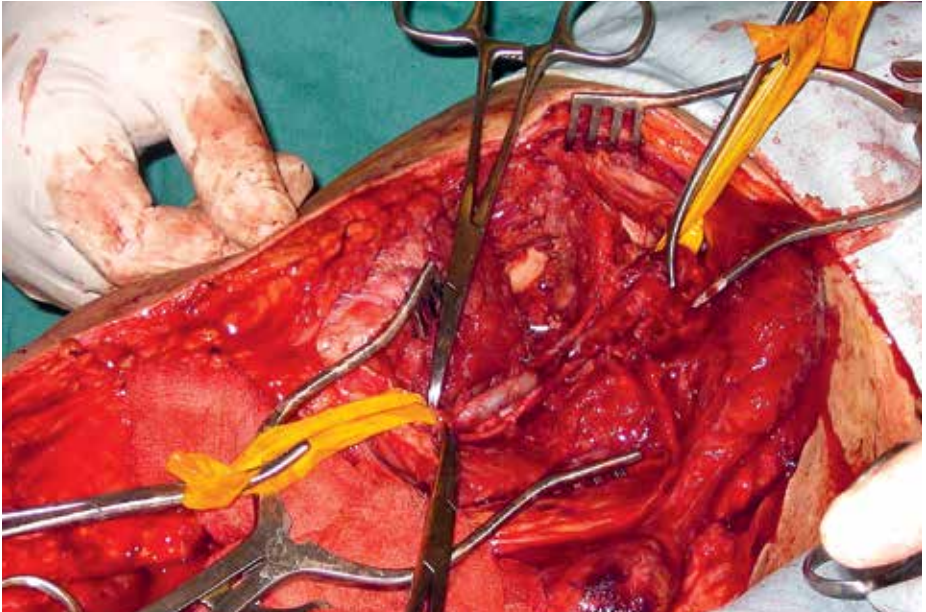
**Figure 28.** Line drawing of placement of tubing for temporary vascular shunt (ICRC)



**Figure 29.** Temporary vascular shunt secured with suture (ICRC)

## KEYS TO VASCULAR SHUNTS

- » The criteria to install a temporary shunt as a bridge to definitive repair will depend on the clinical evaluation of hard and soft signs of vascular injury, but ***the most important factors to consider are the presence of ischemia or hemorrhage.***
- » Many patients with vascular injuries can have a "contained lesion" with no ischemia or active hemorrhage, and they should be moved to the proper facility with no procedures beyond immobilization of fractures.
- » **DURATION OF THE SHUNT:** The shunt should be in place until the second stage of damage control can be safely completed in unstable patients, and for stable patients, until external fixation can be obtained.
- » **HEPARINIZATION:** Distal shunts such as those below the knee tend to obstruct more easily than larger caliber, more proximal shunts. Therefore, the decision for heparinization should be taken based on the presence or absence of other major injuries and the expected time to definitive repair.



**Figure 30.** Effective control and exposure is crucial for successful control or repair of vascular injuries. (ICRC)

## OPEN REDUCTION AND KIRSCHNER WIRE (K-WIRE) FIXATION

Use only single ended K-wires for safety of the operating room staff. Double ended wires have a high risk of injury to staff that outweighs any perceived benefit. Sizes needed are 1.6 and 1.1 mm, and *cerclage wire 16 and 18 Gauge*.

K-wire fixation may be considered early in open fractures of the hands, and less often with open fractures of the feet.

Hand injuries often appear worse than they are and every attempt should be made to keep as many digits as possible, especially the thumb.

Using k-wires may mean that badly injured fingers are salvaged that would otherwise have been lost through instability and further injury to their vascular supply. They should not be used in open long bone fractures.

The insertion of k-wires under power is more accurate and faster than using a hand drill. They are difficult to insert with a hand drill as one hand is necessary to stabilize the segment to be pinned.

Early use of K-wires in open fractures raises the risk of colonization of the wires and subsequent infection. Consider timing of K-wire fixation to minimize infection risk in fractures of the olecranon, patella and to secure large articular fragments.

The olecranon and patella fractures may be amenable to waiting until wounds have healed before proceeding to internal fixation with wires.

However, early use may be advisable in securing articular fragments where the loss of those fragments is a worse outcome than if the wires become infected.

### PITFALL

**NO INTERNAL FIXATION OF FRACTURES OTHER THAN K-WIRE FIXATION IN HANDS AND FEET SHOULD EVER OCCUR IN A TENT.**

Refer local patients needing ORIF (i.e. for intra-articular fracture) to local services. The local teams will be providing follow up and should be involved in the care from the early stages.

## ANTIBIOTICS IN OPEN FRACTURES

- » Antibiotics are an adjunct to wound surgery and not an alternative. The use of antibiotics for open contaminated fractures is limited to 24-72 hours, unless clinical evidence of infection is present.
- » Tetanus prone wounds and uncertainty regarding past immunization should prompt treatment with Immunoglobulin 500 units and administration of the tetanus vaccine

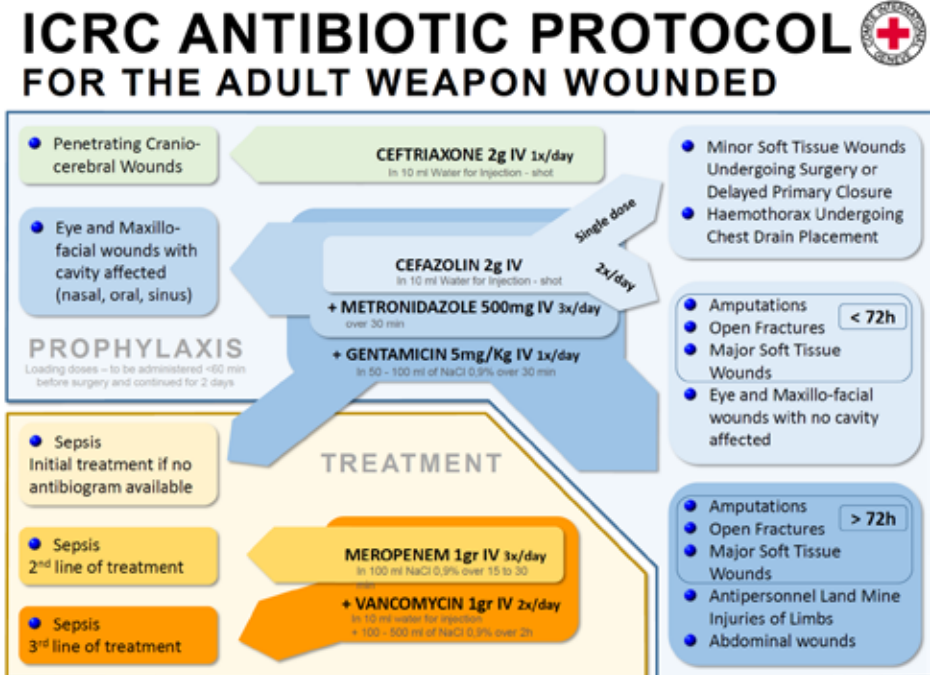


Figure 31. Antibiotic Protocol for Adults with conflict injuries (ICRC)

## SUGGESTED RESOURCES

1. Gosselin RA. War injuries, trauma, and disaster relief. *Techniques in Orthopaedics* 2005; 20(2): 97-108.
2. Herard P, Boillot F. Amputation in emergency situations: indications, techniques and Médecins Sans Frontières France's experience in Haiti. *International Orthopaedics* 2012: 1-3..

## REFERENCES

1. Giannou C, Baldan M. War surgery: Working with limited resources in armed conflict and other situations of violence, Volume 2. Geneva: International Committee of the Red Cross; 2013.
2. Giannou C, Baldan M. War surgery: Working with limited resources in armed conflict and other situations of violence, Volume 1. Geneva: International Committee of the Red Cross; 2009.
3. Dufour D, Jensen SK, Owen-Smith M, Salmela J, Stening GF, Zetterström B. Surgery for victims of war. 1998.
4. Norton I, Von Schreeb J, Aitken P, Herard P, Lajolo C. Classification and minimum standards for foreign medical teams in sudden onset disasters. Geneva: World Health Organization; 2013.
5. Menelaus MB. The management of limb inequality. Churchill Livingstone; 1991.
6. AO Surgery Reference. 2016. <https://www2.aofoundation.org/wps/portal/surgery2016>.

EMT Website: <https://extranet.who.int/emt/page/home>  
 AO/ICRC/WHO Training Resources: <http://www.aofoundation.org/icrc>