

# New Products from AO Development

Norbert P. Haas, AOTK Chairman



021

# NEWS NEWS





Dear Reader,

Thank you for the positive feedback to the first issue of *New Products from AO Development*. We have made several improvements including more X-rays and longer articles on clinical benefits. Nevertheless, we need to stress that none of these articles is a substitute for the OP Techniques and our AO teaching tools. This brochure intends to give you a first overview only. You can get more detailed information about these products from your local SYNTHES® representative.

Most of you are receiving *New Products from AO Development* as a removable supplement to the AO Dialogue. We hope that this way of distribution is most convenient to you. It enables us to provide you with further information about development related information, e.g. the article about the TK-System in this issue of AO Dialogue. The TK-System is an organization of medical-technical committees responsible for the development of all new AO products. This article provides you with an inside view on what's behind AO Development.

Starting with this issue, we will inform you about interesting, applied research results about new products presented in this brochure or results that are going to influence development in the near future. Furthermore, we are aiming to publish more results of clinical studies proving the clinical benefit of AO products.

Let me point out to you that all authors are medical doctors who have participated in the development of the described products. I would like to thank them for their great engagement and contribution to this issue of *New Products from AO Development*.

Yours sincerely,

Norbert P. Haas

## Contents

- 1 Introduction
- 1 Contents
- 2 New Concepts in Spine Surgery
- 6 New Spine Products
  - Cervifix/Starlock: Clamp & Holding Sleeve for Screwdriver**
  - Click'X Dual Core Pedicle Screw**
- 7 New Long Bone Products
  - Medium External Fixator**
    - Single Pin Clamp, 4 Position Drill Guide & Sleeve and 8 mm Carbon Fiber Rod**
  - DHS: Variable Angle Guide**
  - Distal Femoral Nail with Spiral Blade**
  - High Tibial Osteotomy Device: 70 mm Chisel Line Extension**
  - Locking Condylar Plate**
  - Distal Tibia Plate**
  - Locking Compression Plate: Wire Mount**
  - Locking Compression Plate Screw with StarDrive™ Recess**
- 11 New Knee Products
  - Tomofix: Osteotomy Chisel**
- 11 New Paediatric Products
  - Cannulated Paediatric Osteotomy System**
- 12 New Craniomaxillofacial Products
  - 2.0 Mandible Locking Plate: Bending/Cutting Pliers with beak**
  - Subcondylar/Ramus Fixation Set**
  - Reversible Battery Powered Screwdriver**
  - MR Safe Instruments**
  - IMF Screw System**
- 14 New Veterinary Products
  - 3.5 mm Broad LC-DCP Plate**
- 14 New Products from AO Publishing
- 15 Research Results
- 16 Clinical Studies
  - Humerus Block**
  - LCP Distal Radius**

## New Developments in Spinal Surgery

Fusion of one or more mobile segments has been performed for many decades in the treatment of degenerative diseases, deformities and spinal trauma.

Circumferential fusion is established as the most efficient and predictive way to fuse the spine. The use of autologous bone grafts has been associated with problems and failures, therefore, various spacers and other devices have been developed in the last decade and are widely used today.

### Cages

The SynCage made of titanium is widely employed and very successful in clinical use today. The cage design seems to conform very well with the local anatomy in order to achieve a stable construction and also to address the sagittal profile of the spine. Despite its very impressive clinical performance, however, there is currently no convincing data demonstrating the state of the autologous bone graft which is impacted into the cage. Fusion is only obvious in cases where bony bridging occurs out of the cage.

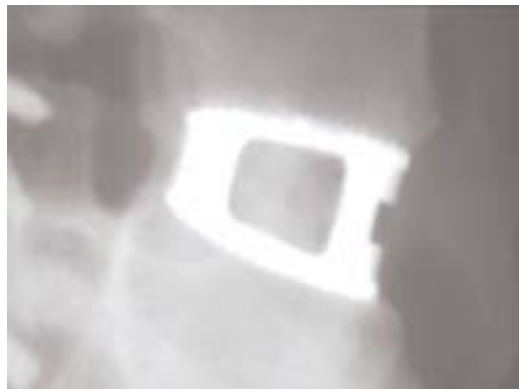

Fig.1 Fusion outside the cage

In most cases we are just “looking” radiologically through the window of the cage but do not know whether there is a vital bony connection running through the cage and connecting the endplates to each other. Different CT-reconstructions produce reasonable pictures of trabecular bony connections through the cage, but there re-

mains the need to have a clear view of the bone inside the cage with plain radiographs.

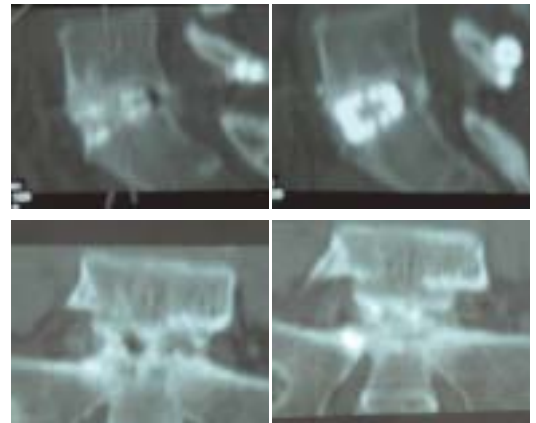


Fig.2 Bone running through the cage

### Radiolucent materials

Cages made of carbon fiber were employed in spinal fusion in the eighties and results were inconsistent. Inflammatory responses resulted in many cases of osteolysis around the cages and established pseudarthrosis. The mechanical integrity of the cages was also the subject of criticism.

After an extensive search we made the choice to employ poly-ether-ether-ketone (PEEK) as a material for interbody fusion cages.

PEEK is a linear and semi-crystalline thermoplastic polymer. Medical grade PEEK has been applied over the past 20 years in medical devices. Up to now, there are no known adverse effects in relation to PEEK devices.

PEEK is a derivative of the PAEK-resins (poly-aryl-ether-ketone) family. The most important features of PEEK material are its biocompatibility, its elastic modulus similar to bone and its radiolucent properties. It is an inert material and its reaction with bone is comparable with titanium.

Different tests show no material cytotoxicity. PEEK is registered in the FDA Device

Masterfile (MAF) and Drug Masterfile (DMF) and is USP class VI approved, according to FDA regulation. It is also ISO certified.

Two design concepts were developed based on the very successful surgical technique for cage impaction in optimal distraction; one copying the design of the titanium cage with some small modifications of the contact surfaces named SynCage-LR, and a second one mimicking the configuration of the vertebral end plates, named Visios.

The development of the SynCage-LR (Fig. 3) met two objectives: adaptation of the cage design to the specific properties of L5-S1 intervertebral space and the creation of a larger footprint for improved conformity to the endplates of large individuals.




Fig.3 SynCage-LR

Visios has a kidney shaped footprint which addresses the strong peripheral part of the end plate. A large central hole facilitates packing the cage with autologous bone graft or bone graft substitutes.

In profile, the Visios uses the same convex characteristics as the SynCage and conforms well with the concave vertebral endplates.



Fig. 4 Visio

Mechanical testing of cage strength was very convincing. In static compression load testing, structural deformation of the SynCage-LR occurred after loads exceeding 44 kN. Fatigue testing with a duration of 5 million cycles and a frequency of 6 Hz, resulted in only a small deformation of the teeth, without any structural changes to the construction.

There was no significant difference in biomechanical performance between the titanium SynCage and the SynCage-LR designs when tested in cadavers.

Clinical studies with SynCage-LR and Visios show similar results, as with the titanium SynCage. Fig. 5 and 6 show the radiological appearance at 3 and 6 months' follow-up. After a year, there is appreciable bony bridging seen through the cages, as shown on CT-reconstructions.

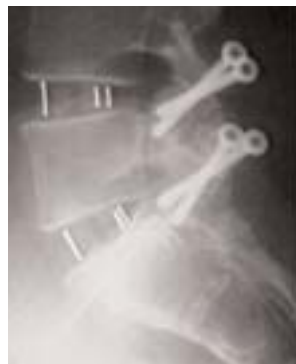

Fig. 5  
3months p.o., Patient A

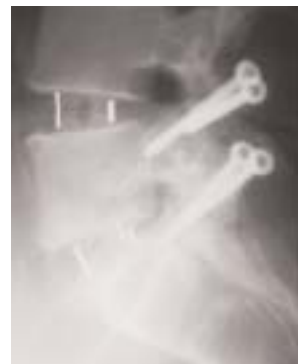

Fig. 6  
6months p.o. , Patient A

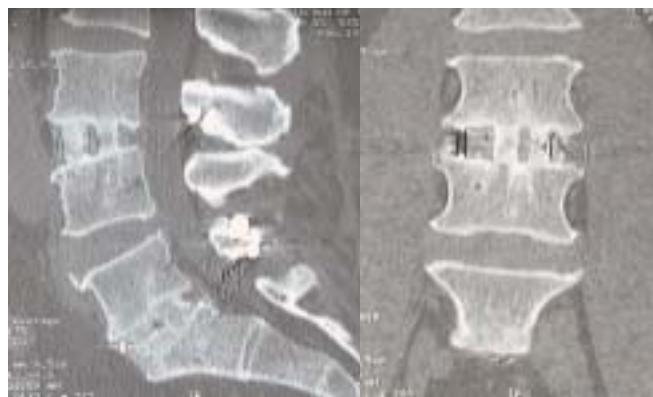

Fig. 7 CT-reconstruction 11 months p.o., Patient B

## Grafts and substitutes

Up to 20% donor site morbidity has been reported with the use of autologous bone grafts. For this reason, surgeons in South Africa have used a registered bone graft substitute called chronOS, which is made of tricalcium phosphate (TCP). Difficulties with filling the individual cages with granules were encountered, which led to a project to fabricate cages which are pre-filled with solid chronOS. Mechanical tests showed satisfactory retention of chronOS, therefore, a sheep model was used to compare fusion outcomes between the chronOS granules-filled cages, solid chronOS-filled cages and autologous bone-filled cages.

Fusion using the chronOS-filled cages was equal to that of autologous bone-filled cages, especially when prefilled with solid chronOS. There is evidence that more than 60% of the chronOS filling resorbed after 26 weeks being replaced by trabecular bone.

Further, in a small series of cervical cages (Cervios, prefilled with chronOS) the clinical results are very convincing.

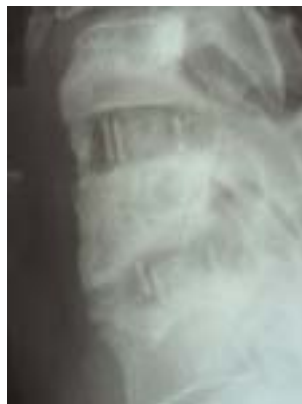

Fig. 8 C-spine fusion 3 months p.o., Patient C

In conclusion, the generation of new lumbar and cervical interbody fusion cages made from PEEK will be employed extensively in the future. The employment of chronOS as a bone substitute will elimi-

nate donor site morbidity and considerably shorten operation time. There is a clear economical benefit, because the elimination of donor site morbidity will result in a shorter hospital stay.

## Osteoporotic fractures of the spine

The ageing spine is a very challenging area because of the increasing number of senior citizens and the lack of impressive results from the treatment and prevention of osteoporosis in elderly people.

In the last twenty years, PMMA bone cement has been employed in the treatment of osteoporosis of the spine. Despite many enthusiastic reports, however, there is a clear under-reporting of dangers and complications when using PMMA for augmentation of osteoporotic vertebrae. There is an increasing number of disastrous complications from the use of PMMA, including paraplegia and death.

A new concept for augmentation of osteoporotic and fractured vertebral bodies has been developed. The idea is to create a cavity in the osteoporotic vertebral body, to reduce fragments if fractured, and then inject a biocompatible high viscosity substitute, which may even be slowly resorbable, in order to achieve high mechanical strength of the injured vertebra. This so-called Cavitation technique employs newly developed instruments which create a cavity in the affected vertebral body.




Fig.9 Creation of cavity within the vertebral body

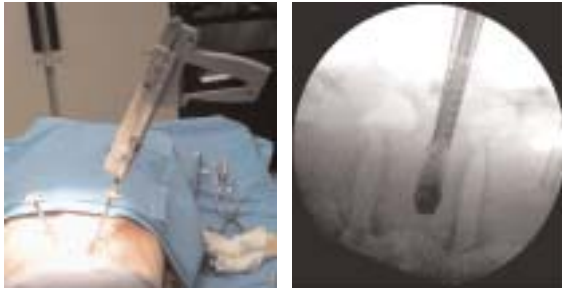

Fig.10 Injection of Norian into cavity

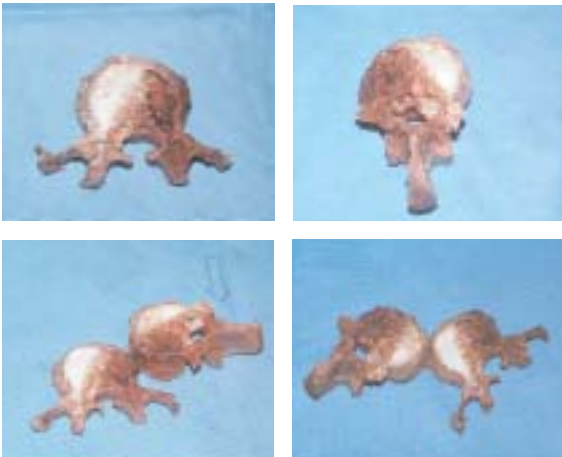


Fig.11 Cadaver specimens half filled with Norian

The major advantage of this technique is the safety of the procedure; the spinal canal and neural elements cannot be violated. There is also no danger of thermal damage when using SRS Norian.

The Cavitation technique is already in clinical use. Early results are very encouraging and it seems to be a safe way to deal with the increasing number of osteoporotic fractures.

#### Non fusion stabilisation

It is recognized that fusion of the spine alters its mechanics and, in the long run, will induce secondary changes in the adjacent vertebrae. There is a clear tendency for the development of new techniques to stabilize the spine without altering motion.

Because of the huge variety of degenerative changes which occur in the spine over

time, we are looking at a number of different tailor-made solutions, in order to address different stages of degeneration. There are different strategies to be followed, starting maybe with tissue manipulation in the very early stages of degeneration. The aim will be to increase the amount of proteoglycans in the intervertebral disc and in this way restore consistency and function. In cases of clear degeneration of the nucleus pulposus, some kind of nucleoplasty may be employed to partially restore the mechanical properties of the disc.

In cases of more pronounced degeneration and extensive distraction of the annulus fibrosus, total disc replacement may be employed.

Today, different projects have been initiated and some prototypes are already undergoing mechanical testing.

From a strategic point of view, it is very important to develop a modular approach to problems of the degenerative spine, with special emphasis on well defined second and third lines of defence. The aim is to cover the entire active life of the individual and to permit normal use of the spine.

## New Spine Products



### StarLock System

The StarLock System was launched in March 2000 and has been well received by many surgeons. On the request of many consultants, a modification to the existing clamps has been added to the system; these are clamps with extended offset and also up-going clamps. The new clamps meet the same functional requirements as the existing clamps. They will increase the flexibility and the application area of the fixation system.

In order to increase safety of the procedure special holding sleeves have been developed. The holding sleeve makes sure that the screwdriver does not slip off the screw accidentally.

### Click'X Dual Core Pedicle Screw

#### Features:

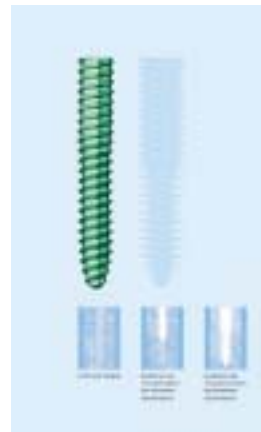
- constant outer diameter
- smaller core diameter in the distal part ⇒ optimal purchase in cancellous bone
- short conical transition to larger core diameter in the proximal part ⇒ minimal loss of grip in case of turning back of the screw
- larger core diameter in the proximal part ⇒ optimal purchase in the pedicle
- round tip ⇒ no danger for segmental vessels in the case of bicortical fixation
- double thread starting at the tip ⇒ immediate purchase of the thread, fast insertion

Indications for the new Click'X Dual Core Pedicle Screws are the same as for the well known cylindrical Click'X Pedicle Screws in the lower thoracic and the lumbar spine:

- Degenerative instabilities
- Instabilities following decompression
- Tumours without anterior defect
- Fractures without loss of ventral support

Deformities, fractures and tumors which primarily effect the anterior column should not be treated in the first step with the Click'X Dual Core Pedicle Screw. However, an additional posterior fixation after anterior stabilization might be suitable.

The new Click'X Dual Core Pedicle Screws are available in the following diameters: 5.2mm, 6.2mm, 7.0mm, 8.0mm, 9.0mm. The last two diameters are thought to serve as emergency/revision screws or for sacral fixations.





## New Long Bone Products



D. Höntzsch

Medium External Fixator

The Modular Tube/Rod External Fixator of the AO is now available in four sizes: Large (11mm), Medium (8mm), Small (4mm), and Mini (2mm).

The Large, Medium and Small Ex Fix have similar clamps, rods and screws:

- Single Pin Clamps for pin to rod/tube connection
- Multi Pin Clamps for multiple pins
- Combination Clamps
  - for rod/tube to rod/tube connection
  - for pin to rod/tube connection
  - for pin to pin connection (in future)

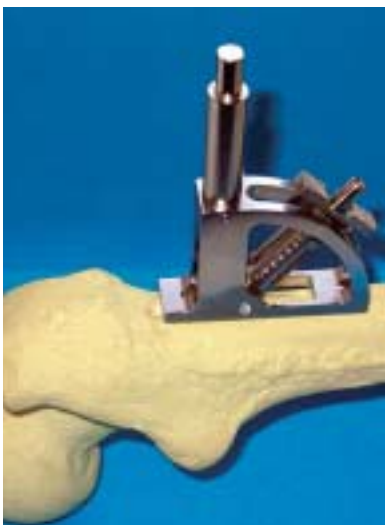Tube and rods are available in steel and/or carbon fiber. The Schanz screws are self-tapping or self-drilling in steel and titanium. All clamps will be "open" and "snap on". The clamps will be colour coded for each size. The standard frame is the "3 Tube Modular Technique".

Lately, the Medium External Fixator was completed. The Medium Ex Fix is indicated for the stabilization of medium sized bones: the foot, forearm, elbow, humerus and small adult's tibia and children's long bones. The combination "up" to the Large 11mm and "down" to the Small 4mm System is possible and one of the main indications. Indications for the Medium Ex Fix are identical to the classic indications for external fixation: fractures with severe soft tissue damage (closed and/or open), polytrauma, septic cases etc.

---

Variable Angle Guide for DHS

The DHS system is considered the standard implant for the stabilisation of most proximal femoral fractures. One single Variable Angle Guide enables surgeons to introduce the guide wire for the hipscrew under different angles. The Variable Angle Guide locks in angles of 130°, 135°, 140°, 145° and 150°.

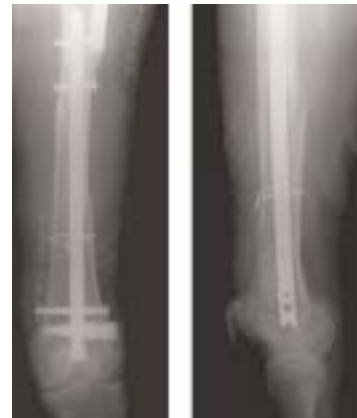
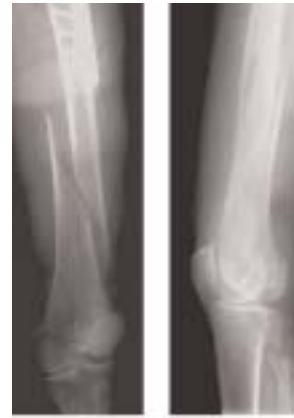

Distal Femoral Nail with Spiral Blade (see also article on page 15)

In the past years, retrograde femoral nailing has proven to be safe and reliable. The Distal Femoral Nail is becoming increasingly popular and is especially suitable for obese (or pregnant) patients and in osteoporotic metaphyseal bone.

Indications include extra-articular metaphyseal distal femoral fractures (32-A1 to C3) and supracondylar fractures and simple articular fractures (33-A1 to A3 and 33-C1 to C3.1).

The Spiral Blade enables significantly more stable distal interlocking than with conventional locking bolts due to the large load-bearing surface. It reduces cancellous bone compaction and lowers the risk of nail protrusion into the knee joint. The nail diameters are 9.0 and 10.0 mm for solid nails and 12.0 mm for cannulated nails. Lengths range from 160 to 420 mm.



Female, 88 y.

High Tibial Osteotomy (HTO)

Device: 70mm Chisel Blade Line Extension

Longer chisel blades have been requested for performing osteotomies of the proximal tibia. This extension of the existing SYNTHES® Chisel Blade Line provides the surgeon with 20 mm of additional functional length. The 70 mm Chisel blades –from 440A Stainless Steel–are available in the standard 5, 10, 16 and 25 mm widths and are compatible with the existing Chisel Handle.




LCP Distal Femur Plate

The Locking Compression Distal Femur Plate or Condylar Locking Compression Plate is indicated primarily for extra- and intra-articular distal femur fractures (32-A1 to C3, 33-A1 to A3 and 33-C1 to C3).

The implant is anatomically pre-shaped and has Locking Compression Holes in the shaft, a limited contact profile and locking screws in the head. The primary feature of the system is its ability to use either locking or compression screws. Locking screws in the head of the plate form an angular stable screw-plate construct.

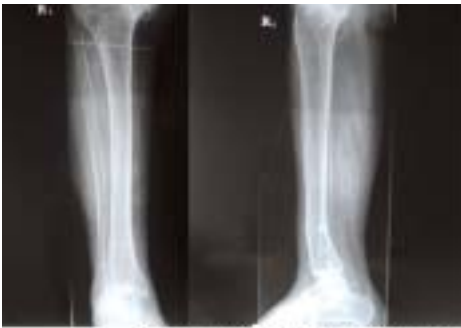The combination holes are compatible with all AO 4.5 mm LCP and conventional screws and technique. The Condylar Locking Compression Plate utilises the Locking Periarticular Plating System instrumentation. The plate is available in Stainless Steel.



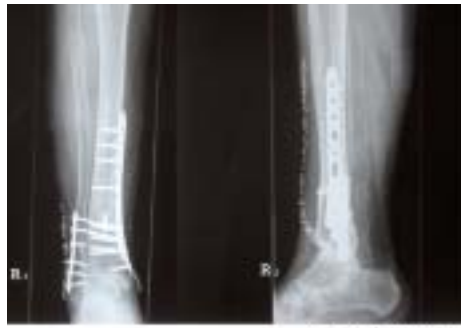

### LCP Distal Tibia Plate

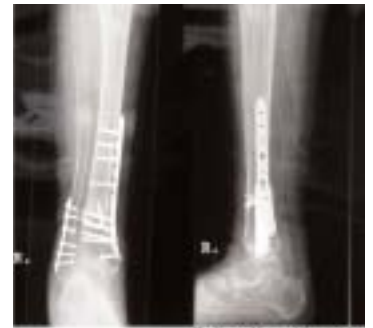The Distal Tibia Plate is anatomically pre-shaped and locked screws provide angular stability. In the shaft area this plate has a standard dimension and a limited contact profile, more distally the plate gets thinner to spare the delicate soft tissues over the medial tibia. It is of special advantage in osteoporotic bone, where the anatomical design supports the reduction and allows percutaneous application. Indications are extra- and intra-articular fractures of the distal tibia (43 A1 to A3 and C1 to C3), especially with osteoporotic bone and/or with injury to the overlying soft tissues. The Distal Tibia Plate is available in Stainless Steel and Titanium, they are fully compatible with all 3.5 conventional screws, with the 3.5 Locking Compression Plate System and with the Calcaneus Locking Plate Set.



89y 4- accident 8781, strong Osteoporosis



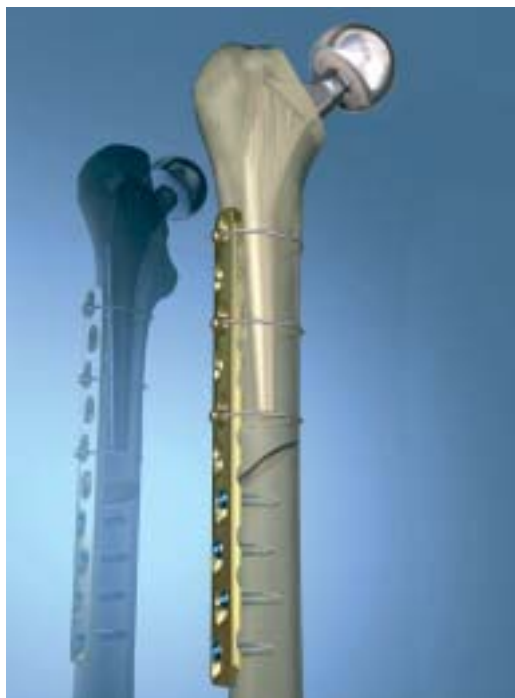Operation, 09.08.01



Follow Up - 12 weeks

### LCP Wire Mount

The Wire Mount for LCP 4.5/5.0 plates facilitates the additional use of cerclage wires in plate fixation of shaft fractures in general, but of periprosthetic fractures in particular. The Wire Mount is inserted in the selected plates hole and guarantees a fixed position of the wires in direct relation to the underlying plate. It is available in Stainless Steel and Titanium.



S. Perren

Stardrive™ a new AO screw drive connection

Some 40 years ago the AO selected the hexagonally recessed screw drive connection. In comparison to single and cruciate slots, the HEX offers a good lateral guidance that allows “blind” insertion and removal. In comparison to Phillips, the torque transmission is largely independent of axial thrust, which may compromise initially unstable reduction of the fracture fragments. Furthermore, to avoid collision of sequentially inserted plate or lag screws the surgeon knew the inclination of a HEX screw of which only the head protrudes from the bone because the screw driver by necessity aligns with the screw axis.

Still, the flats of the HEX screw-driver and -recess are oriented rather tangentially to the force applied. Such torque transmission may strip and results in a tendency to expand the screw head with application of torque. This is the case especially when the screw driver is worn. The new AO Stardrive™ maintains the advantages of the HEX but offers a better resistance to stripping, as the flats are orientated more perpendicularly to the force applied. A further advantage of the new AO Stardrive™ is that the size of the drive connection now conforms to general technical standards.

The Stardrive has been successfully introduced in the area of maxillo-facial and spine surgery. Further applications such as in the long bones are under close investigation.

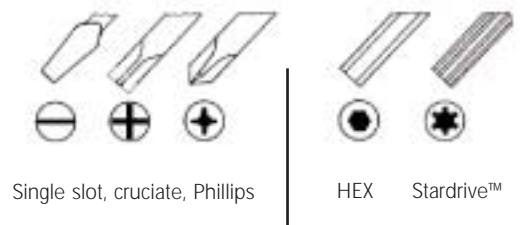


Fig. 1: Different types of screw drive connection.



Fig. 3: Appearance of the two different drive connections of screws according to the function of the screw used in the LCP. The locked screws are fitted with Stardrive™, the conventional screws are fitted with HEX drive.

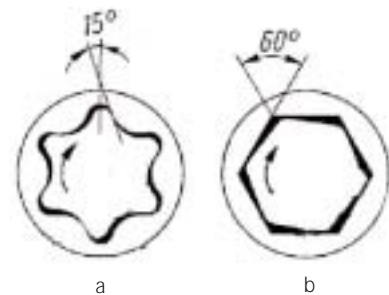


Fig. 2: Comparison of force transmission upon application of torque at insertion/removal between Stardrive™ and HEX

Fig. 2a: Stardrive™: the force is exerted nearly perpendicularly to the flats of the screw, therefore the transmission of torque is superior

Fig. 2b: HEX: the arrows show that force during application and removal is exerted rather tangentially to the flats of the screw drive.

A. Gächter

## New Knee Products



TOMOFIX: Osteotomy Chisel

Open wedge osteotomy of the tibia seems to have several advantages over closed wedge osteotomy, including reduced risk of neurologic damage (e.g. peroneal nerve), no shortening of the medial tibial and easier insertion of a future knee arthroplasty if necessary. In addition, the elevation of the proximal tibia can be adjusted more posteriorly or anteriorly according to needs. On the other hand, it is difficult to maintain the open wedge situation with conventional implants.

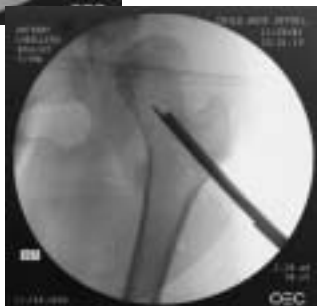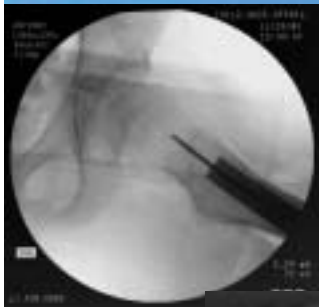For the osteotomy, one can use newly developed chisels with rounded edges and measuring scales to determine the depth of penetration. They also come in different widths.

The locking plate system creates ideal conditions for a stable situation. The gap can be filled with bone or bone substitute. Normally, a gap up to 1.2 to 1.5 cm fills without the need of bone graft.

All osteotomies around the knee achieve optimal fixation with the TOMOFIX system.

J. Hunter

## New Paediatric Products



Cannulated Paediatric Osteotomy System (CAPOS)

The AO series of angled blade plates for children (infant, toddler, child, adolescent) are essential implants for proximal femoral osteotomy providing strength, accurate correction, and a good hold, particularly in soft bone such as in cerebral palsy (CP).

Users have found placement of the chisel difficult, especially in the deformed and narrow proximal femur frequently found in CP. The CAPOS system provides for insertion of the chisel over a guide wire, after insertion of the guide wire through an adjustable angled guide for precision osteotomy. Another feature is a cutting block that attaches to the chisel after placement; this ensures that the proximal osteotomy cut is firstly, the correct distance from the chisel to accommodate the plate offset, and secondly, parallel to the chisel. The plates have not been cannulated at this stage. With a single chisel track in the femoral neck it was felt that it should be easy to place the implant. We believe that CAPOS will extend the life of classical AO implants well into the 21<sup>st</sup> century and look forward to users feedback.

## New Craniomaxillofacial Products

Bending Cutting Pliers with Beak for 2.0 Mandible Locking Plate

The Bending Cutting Pliers with beak is designed for the 2.0 Mandible Locking System and combines two features in one instrument. Bending over the plane and the edge as well as cutting of the plates are easily possible.

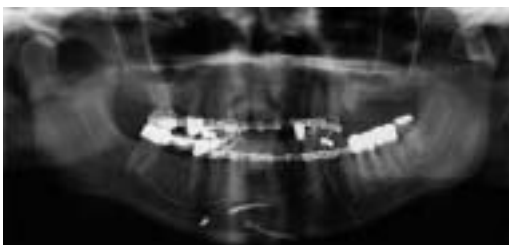
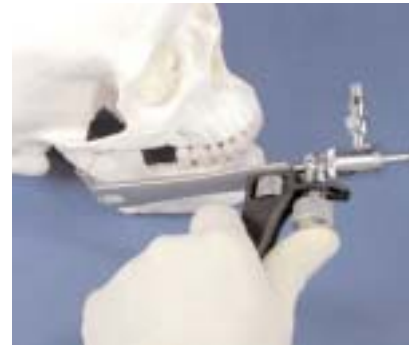

Subcondylar/Ramus Fixation System

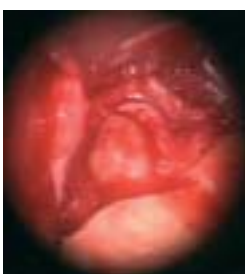The Subcondylar/Ramus Fixation System is comprised of instrumentation to support endoscopic treatment of fractures and orthognathic procedures involving the ramus and subcondylar regions of the mandible.

Open reduction and internal fixation of subcondylar and ramus fractures and osteotomies of the mandible have proven challenging to surgeons; often requiring surgical approaches that provide sufficient exposure in order to permit clear visualization of the reduction and application of the fixation device. Open reduction is often controversial due to the difficult access to this area and the potential morbidity related to nerve damage. In addition, large incisions often resulting in collateral tissue damage and scarring are regarded as costs that must be weighed against the benefits of the procedure.

Endoscopic technology significantly reduces the invasive aspect of many surgical procedures. Synthes Maxillofacial and the AO Maxillofacial Expert Group have developed appropriate instrumentation to support endoscopic, minimally invasive surgical techniques in treating subcondylar fractures.

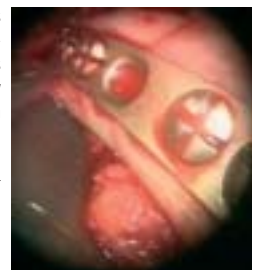

1. Panoramic radiograph preoperatively of a severely dislocated bilateral condyle fracture. Lag screw fixation of the median mandibular fracture was performed prior to admission in another clinic. Note the severely dislocated fragments with medial override on the right and medial displacement with shortening of the ascending ramus on the left side.

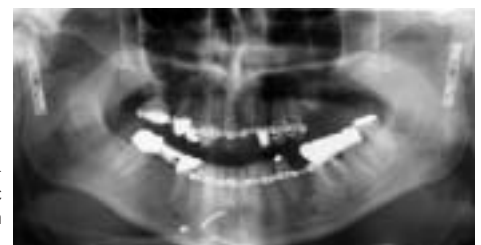

2. Intraoperative view by a 30 degree angled endoscope of the dislocated condyle fracture on the right side. The condylar fragment was dislocated with medial override.

3. The condylar fragment was reduced by the special instruments of the Subcondylar / Ramus Fixation System. Endoscopic view after osteosynthesis with a 2.0mm titanium miniplate. The alignment of the fragments was controlled endoscopically at the posterior aspect of the ascending ramus.



4. Panoramic radiograph postoperatively after endoscopic assisted reduction and fixation of both condylar fractures.



### Battery Powered Screwdriver with Reverse

The Battery Powered Screwdriver (BPS) is a cordless instrument that assists in the placement of bone fixation screws, tapping and drilling. The handpiece with Reverse is an addition to the BPS system that currently consists of a forward handpiece, Rechargeable Battery Pack and Battery Charger. The addition of a reverse mode on the screwdriver will enable surgeons to remove screws as well as to power tap. A full line of taps for resorbable screws will be introduced with this handpiece.

The current method of manual tapping in order to place resorbable screws is technique sensitive and frequently leads to stripped or non-functional holes due to excessive wobble caused by surgeon fatigue and motions of the wrist. The Battery Powered Screwdriver with Reverse allows the surgeon to tap consistently every time with little or no wrist action. The combination of self-drilling taps and a battery driven handpiece offers a clear advantage over the competition in the resorbable market in terms of reducing OR time and surgeon fatigue.




### MR Safe Instruments

MR Safe Instruments, comprised of a variety of taps, screwdriver blades, one drill bit and one screwdriver handle with mini-quick coupling, are to be used in magnetic resonance imaging procedures.

Most medical device instruments used in an MRI Suite are manufactured from non-magnetic materials such as L605, MP35N or 316LEH. The MR Safe Instruments will be manufactured from MP35N (blades, taps and drill bit) and 316LEH stainless steel (screwdriver handle) because they are stronger and have better wear characteristics compared to the L605 material. All

of the instrument designs already exist as standard SYNTHES® products.

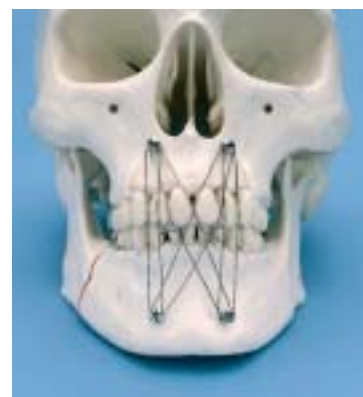The MR Safe Instrument Project was initiated to meet the needs of those surgeons who perform operations in a MRI Suite or a MRI Environment, which is highly magnetic. Instruments made out of materials, such as 440A and X15-TN stainless steel are highly magnetic and can be extremely dangerous to both the patient and those performing or assisting in the operative procedure.



### IMF Screw System

The IMF Screws are indicated for craniofacial and mandibular trauma and reconstruction, plus orthognathic surgery. They are specifically used in the occlusion and fracture stabilization of the maxilla and mandible.

IMF (also referred to as maxillo-mandibular fixation, or MMF) is a commonly applied, fundamental technique of wiring the jaws together in trauma and reconstruction procedures. The IMF screw offers the advantage of a self-drilling tip and easily identified wire holes that will provide a simple and quick method for achieving intermaxillary fixation in simple fractures. Generally, between two-and-four screws are placed into each mandible and maxilla and then connected and tensioned with wire to establish and maintain occlusion.



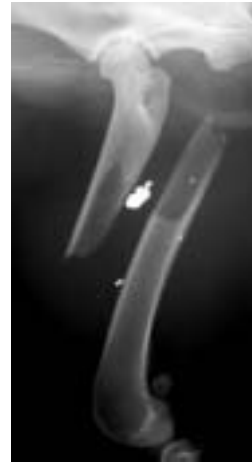J. Auer / D. Hulse

## New Veterinary Products

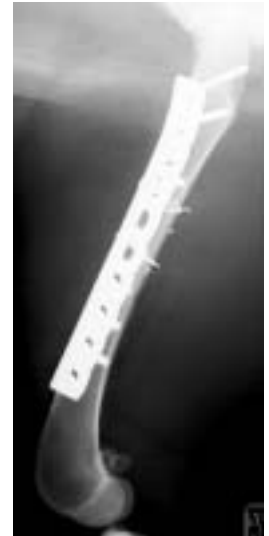3.5 mm Broad LC-DCP

The Reinforced 3.5 mm DCP is a very popular implant in small animal surgery because it is stronger than the narrow 4.5 mm plate, contains more holes than the same length Narrow 4.5 mm DCP and the 3.5 mm cortex screw contains more threads than the 4.5 mm screw. All these parameters result in a stronger construction. The fact that the 3.5 mm LC-DCP system did not include a broad plate prevented many small animal surgeons from changing to the LC-DCP system. This was the main reason to develop such a plate.

The 3.5 mm Broad LC-DCP is made from 4.5 mm Narrow LC-DCP plate stock. The LC-DCP looks significantly wider but in reality there is only a difference of 1.5 mm. Not only were all LC-DCP features converted but staggered holes to increase torsional stability and reduce stress risers from in-line screw holes were added as well. The only change for veterinary surgeons is the need to adapt to the DCU and Universal Drill Guide.



5 year old, 55 lb, male cow.  
Sustained a low velocity gunshot wound to the left thigh.  
Type I open fracture.



No early post operative complications. Early return of weight bearing function.

R. Egle

## New Products from AO Publishing

As you are reading this, the 2001-2 Edition of the AO Image Collection-AO Principles of Fracture Management will be released. It contains over 1000 images, including LCP, used in the current AO PFxM (edition 2001).

AO Publishing is planning to release the companion to AO PFxM: The AO Manual Series. The first edition will cover Upper Extremities. While the AO PFxM represents a classical text book (illustrations supporting the text), the AO Manuals will consist mainly of illustrations supported by text. The authors are submitting cases documented with pictures and intra-operative videos. The publications will be available in print with CD-ROM and Internet-update; as introduced with the AO PFxM. We expect the first edition to be ready for the December course.

Visit us on the internet at: [www.aopublishing.org](http://www.aopublishing.org)





E. Schneider & K. Ito

## Distal Femoral Nail

### A Scientific Study from the AO Research Institute

**Objective:** Intramedullary nail locking bolts often fail to gain purchase or cut out in osteoporotic bone. The biomechanical stability of a bladeliike device that lowers intraosseous stress levels by distributing the load over a greater volume of bone was compared with conventional locking bolts in osteoporotic bone.

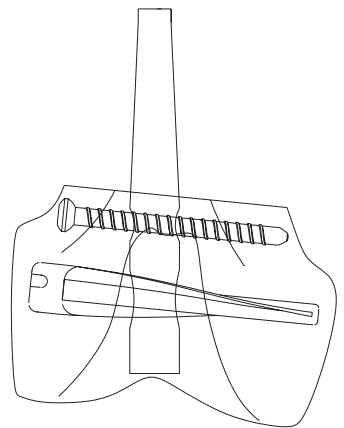
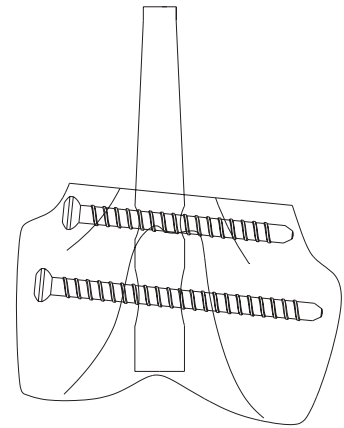
**Methods:** Standardized simulated comminuted supracondylar femoral fractures (segmental defect) in fresh-frozen paired osteoporotic (bone mineral density <200 milligrams per cubic centimeter) human cadaveric femurs were stabilized with a retrograde unreamed distal femoral nail and distally interlocked with conventional locking bolts or a bladeliike device. The distal portions of the fixator-bone constructs were tested under axial load, and the stiffness and strength were compared (pairwise).

**Results:** Interlocking with a bladeliike device was 41 percent stiffer ( $p = 0.01$ ) and 20 percent stronger ( $p = 0.02$ ) than that with conventional locking bolts. All posttesting radiographs showed compaction of the cancellous bone distal to the interlocking devices. Even after nail displacements of twelve millimeters, only a few locking bolts were plastically deformed and no bladeliike device showed gross plastic deformation.

**Conclusion:** This study showed the biomechanical benefits of increasing the bone-implant interface surface for improving the acute stiffness and strength of fracture fixation in osteoporotic cancellous bone. The fixator-bone construct withstood higher forces before failure in these fragile bones.

**Reference:** Ito, K., Hungerbühler, R., Wahl, D., and Grass, R.: Improved intramedullary nail interlocking in osteoporotic bone. *Journal of Orthopaedic Trauma*, Vol. 15, No. 3, pp. 192–196, 2001.

(see also article on page 8)



Interlocking with conventional bolts (above) and the bladeplate device (below)

## Studys

### Humerusblock

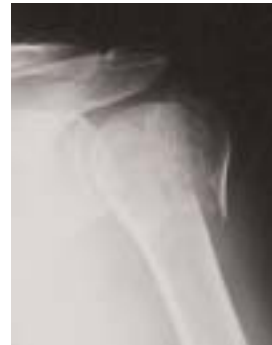The “Humerusblock” described in the last issue was made available to a selection of surgeons in November 2000 as part of a documentation series. The aim of this documentation series was to record the results of first applications with the new implant.

In the context of this series 16 cases were documented. The fractures included 7 subcapital humerus fractures, 6 subcapital humerus fractures with additional fracture of the greater tubercle and three 4-fragment fractures. A “closed” surgical procedure was performed in all cases. The surgeons generally made use of K-wires with a diameter of 2.2 mm and no thread. The use of additional screws was necessary in 8 cases.

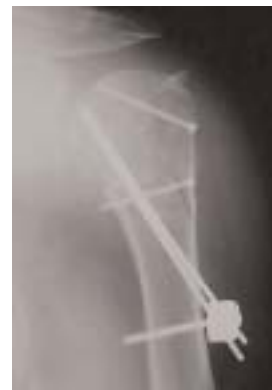Follow-up assessment was carried out in 14 of the 16 cases. In 13 cases fracture consolidation was described by the treating physician; in one case delayed healing was suspected. Slight impaction was observed in four cases and more severe impaction in two cases. Impaction can be regarded as a desirable event. In relation to the implant, the K-wires act as a sort of splint so that impaction occurs in a controlled manner. Dislocation of the humeral head was not observed in any case. In 11 patients, the K-wires perforated the articular surface; this occurred 6 times intraoperatively and 5 times postoperatively. Primary and secondary perforation of the K-wires through the articular surface indicates that the K-wires need to be placed in the immediate subchondral region in porous bone if they are to find sufficient anchorage. Therefore, implant removal after fracture healing or prior to mobilization is necessary; the surgeon may possibly have to withdraw some of the K-wires slightly early on. The following complications occurred during the healing process: local wound irritation above the implant (2 cases; due to incorrectly clipped K-wires) and skin perforation by a K-wire (1 case). In one case, reduction of the greater tubercle was lost in a 4-fragment fracture; reoperation to stabilize the fragment was necessary. There was probably delayed union in one case of a 76-year-old patient. Infections and / or nerve lesions were not observed in any case.

In contrast to conventional K-wire osteosynthesis, the “Humerusblock” permitted the surgeons to perform adequate stable fixation of proximal humerus fractures. Compared with fracture treatment by plate osteosynthesis, this procedure is far less invasive with maximal conservation of the fracture fragments residual vascularity. The conclusions that can be drawn from this series are limited by the small number of patients included (n=16) and followed up (n=14). It can be stated that it proved of value in all the participating centers and that with further application a set of suitable indications will no doubt emerge.

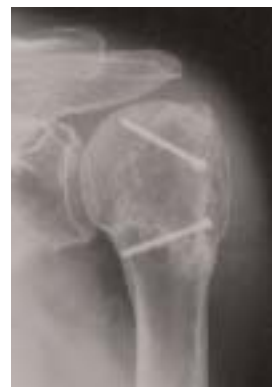62 year old female patient



accident



postoperative



fracture healed

L. Huysse

An outlook on the LCP Distal Radius Studie  
(Locking Compression Plate)

One of the key objectives of AOCID is to organize and conduct clinical studies that provide evidence regarding the clinical benefit of AO methods and implants. The “gold standard” study design to achieve this is a randomized clinical trial (RCT). We therefore considered this design for the LCP distal radius study right from the start.

While simple on paper, the process of randomization met with some practical obstacles. Which treatment would be optimal to compare the LCP with? For which indication? Would surgeons be prepared to randomize patients? In fact, we could not find a consensus on the best control treatment, since the new LCP plate is based on a new concept and does not replace an existing system on a one by one basis. An RCT was judged inappropriate, in particular because surgeons were convinced that the LCP will provide a better outcome for the patient and therefore were not willing to use the conventional system any longer.

The best compromise was to conduct an observational study where the treatment decision remains in the hand of the surgeons. This design allows documentation of the range of indications for treatment with the LCP, and both clinical and radiological outcomes, after plating of the distal radius. By collecting data from a large number of cases, we will identify different cohorts (e.g. patients treated with different plates) that will be compared.

The LCP Distal radius study includes three prospective studies and one retrospective study.

- “Conservative” distal radius study in the UK documenting all distal radius fractures, and all types of treatment (majority of fractures treated conservatively).
- LCP 3.5 mm distal radius study, involving centers mainly using the 3.5 mm LCP system (10 centers).
- LCP 2.4 mm distal radius study, focused on the 2.4 mm LCP system (6 centers).
- Retrospective study documenting the treatment of all distal radius fractures in the past year (before the LCP plate was available). The same clinical journal form is used, with no follow-up visits, and no collection of X-ray images (7 centers).

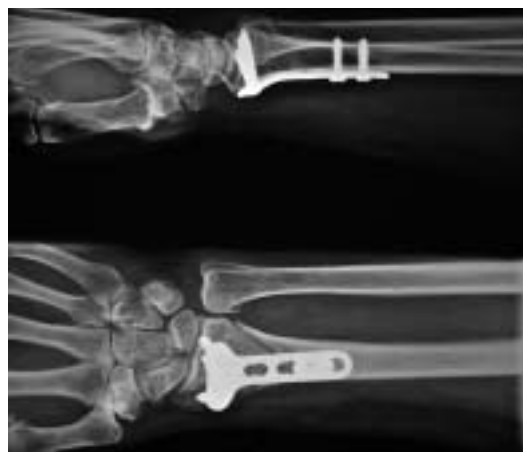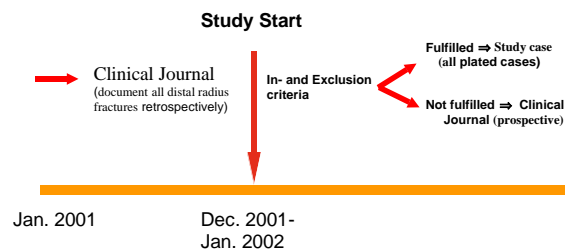
We have two types of questionnaires for the prospective studies, one for all plated cases (any type of plate and fulfilling inclusion and exclusion criteria), including follow-up forms up to two years post-operatively, and a shorter one for all other cases (making the clinical journal).


A schematic overview of the LCP 3.5 mm and 2.4 mm study, combined with the retrospective study is shown in the figure below. The same inclusion and exclusion criteria, as well as clinical (including the Gartland and Werley, the DASH and the SF-36 scoring systems) and radiological (centrally evaluated) outcome criteria are used in the different prospective studies. While follow-up is implemented for all cases in the “Conservative” distal radius study, only plated cases are followed in the two other prospective studies.

Special attention will be given to the expected advantages of the

new LCP concept as well as to maintenance of reduction, the additional use of bone grafting, and the learning curve. The studies are controlled in order allow a comparison of the LCP systems to other conventional plating systems and conservative treatment of distal radius fractures. The retrospective part of the study (documenting the situation before the introduction of the LCP system) will show whether any shift in indication from e.g. external fixator to the LCP system has occurred and in order to define a control group accordingly for future studies.

The different studies were started at the end of 2001.





Editors:  
Univ.-Prof. Norbert P. Haas, AOTK Chairman  
E-mail: [norbert.haas@ao-asif.ch](mailto:norbert.haas@ao-asif.ch)  
P. Schreiterer  
E-mail: [philip.schreiterer@ao-asif.ch](mailto:philip.schreiterer@ao-asif.ch)

Publisher: AOTK  
Layout: AO Media Services  
Print: Gonzen Druck AG, CH-Bad Ragaz

Number of Copies: 20000  
Issued: May 2002

For further information please contact:  
TK Office  
Clavadeler Strasse  
CH-7270 Davos Platz  
Tel.: +41 81 4142-471  
Fax: +41 81 4142-290  
E-mail: [aotk@ao-asif.ch](mailto:aotk@ao-asif.ch)