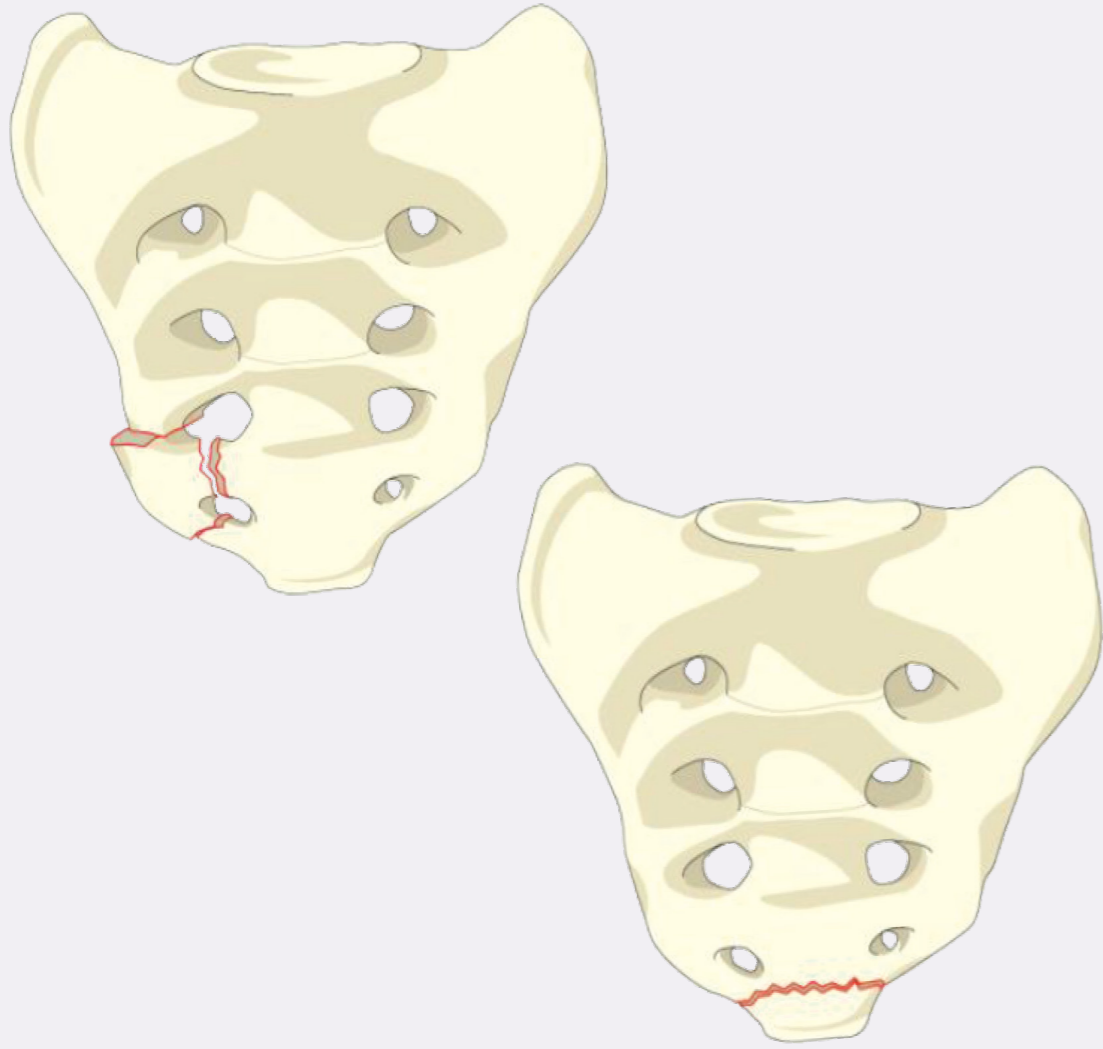


## Type A

### Lower Sacrococcygeal Injuries

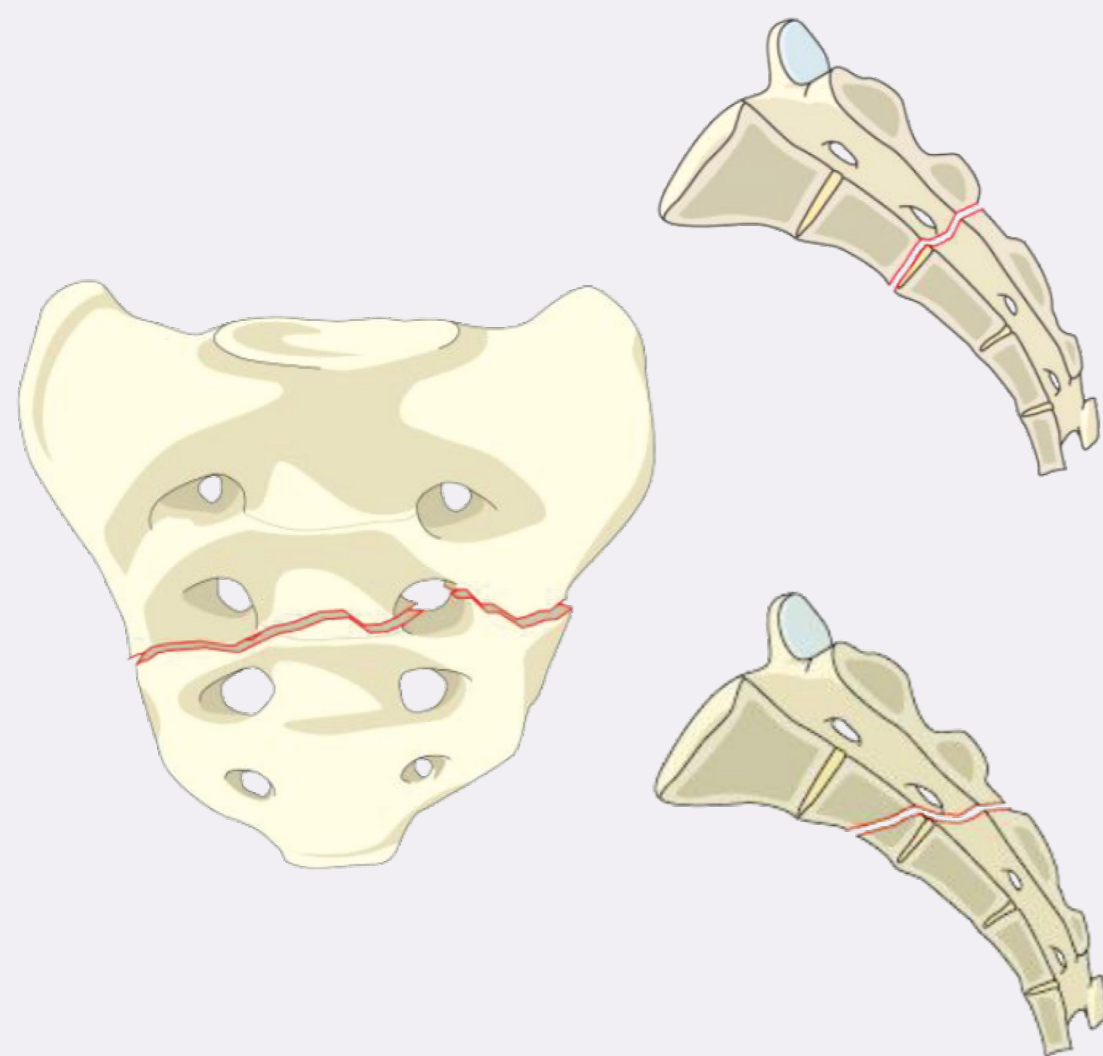
No impact on posterior pelvic or spino-pelvic instability

#### A1 Coccygeal or compression vs ligamentous avulsion fractures



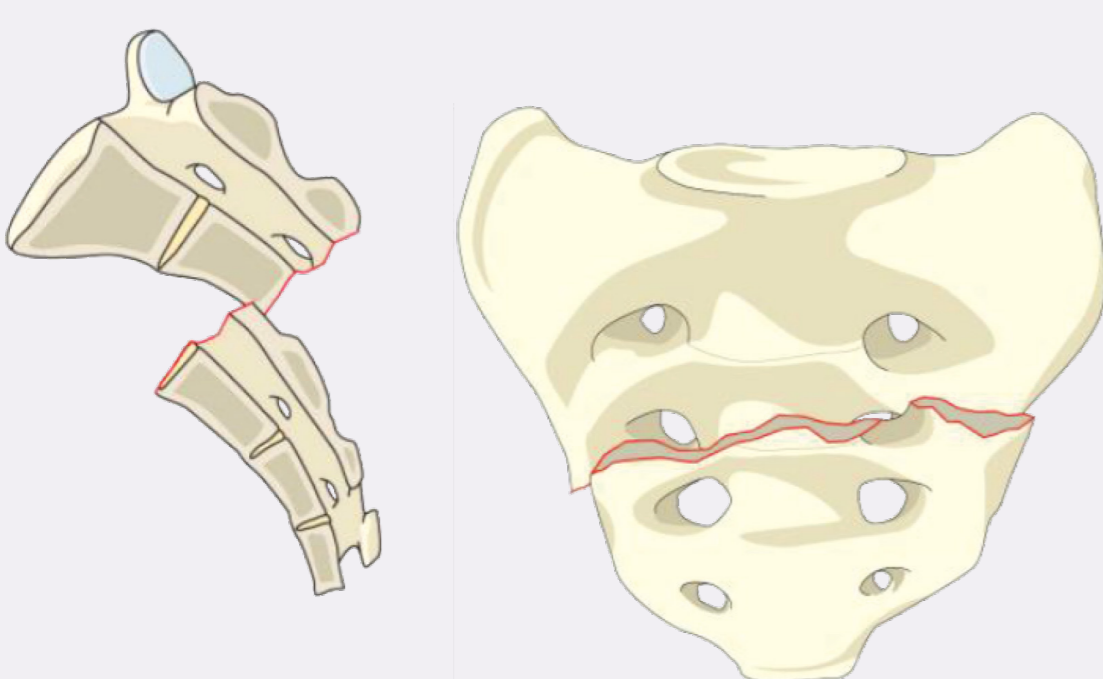
#### A2 Non-displaced transverse fractures below the S-I joint

- No implications on stability
- Low likelihood of cauda equina injury



#### A3 Displaced transverse fractures below the S-I joint

- Higher likelihood of neuro injury than A1 or A2 (displacement)
- May possibly benefit from reduction and stabilization



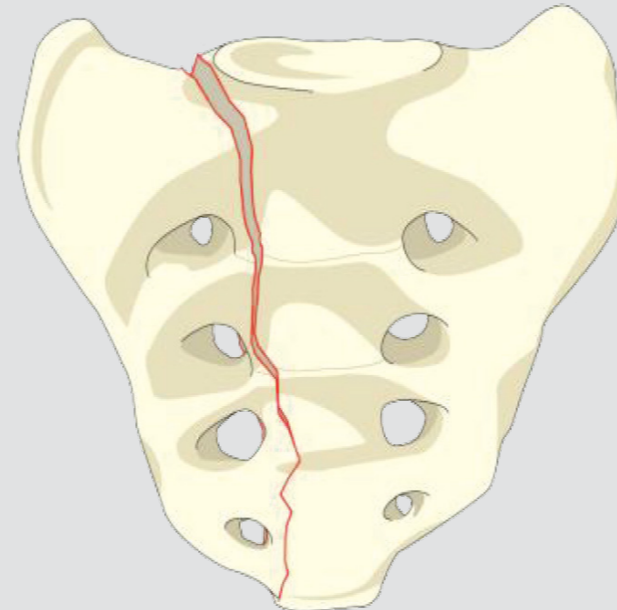
## Type B

### Posterior Pelvic Injuries

Primary impact is on posterior pelvic stability

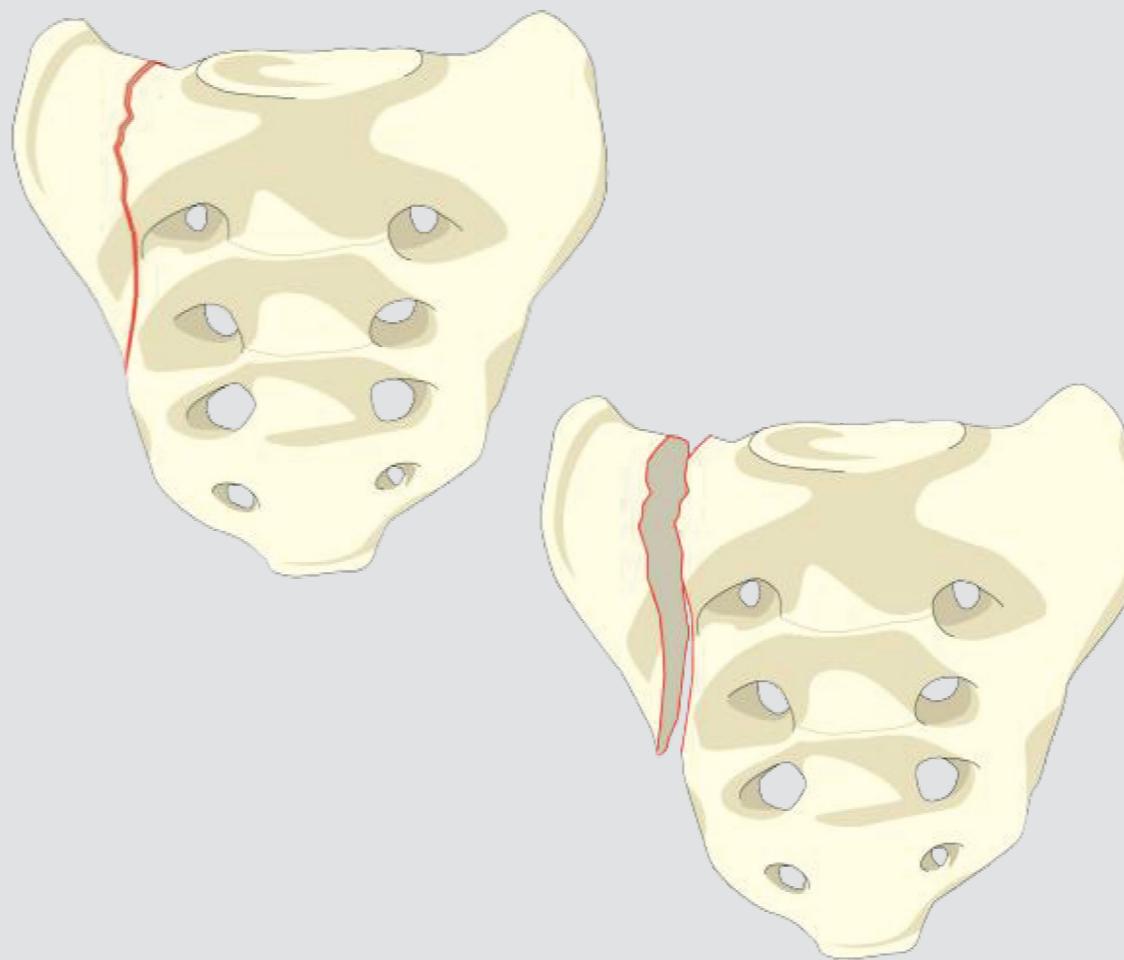
#### B1 Central Fracture—involves spinal canal

- Longitudinal injuries only—rare type of Denis Zone III injuries
- Low likelihood of neurological injury



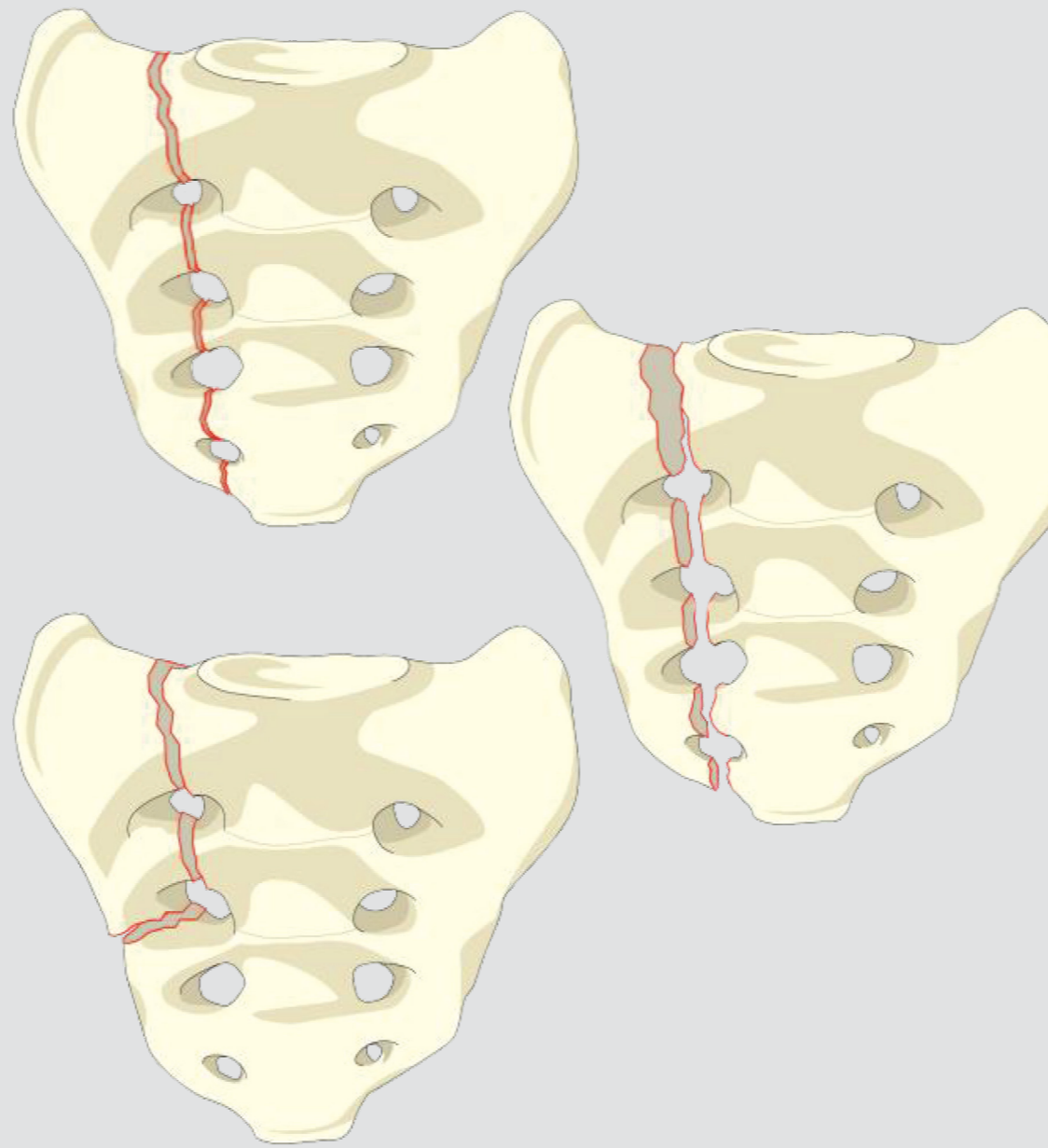
#### B2 Transalar Fracture—does not involve foramina or spinal canal

- Unilateral Denis Zone I injury



#### B3 Transforaminal Fracture—involves foramina but not spinal canal

- Denis Zone II injury



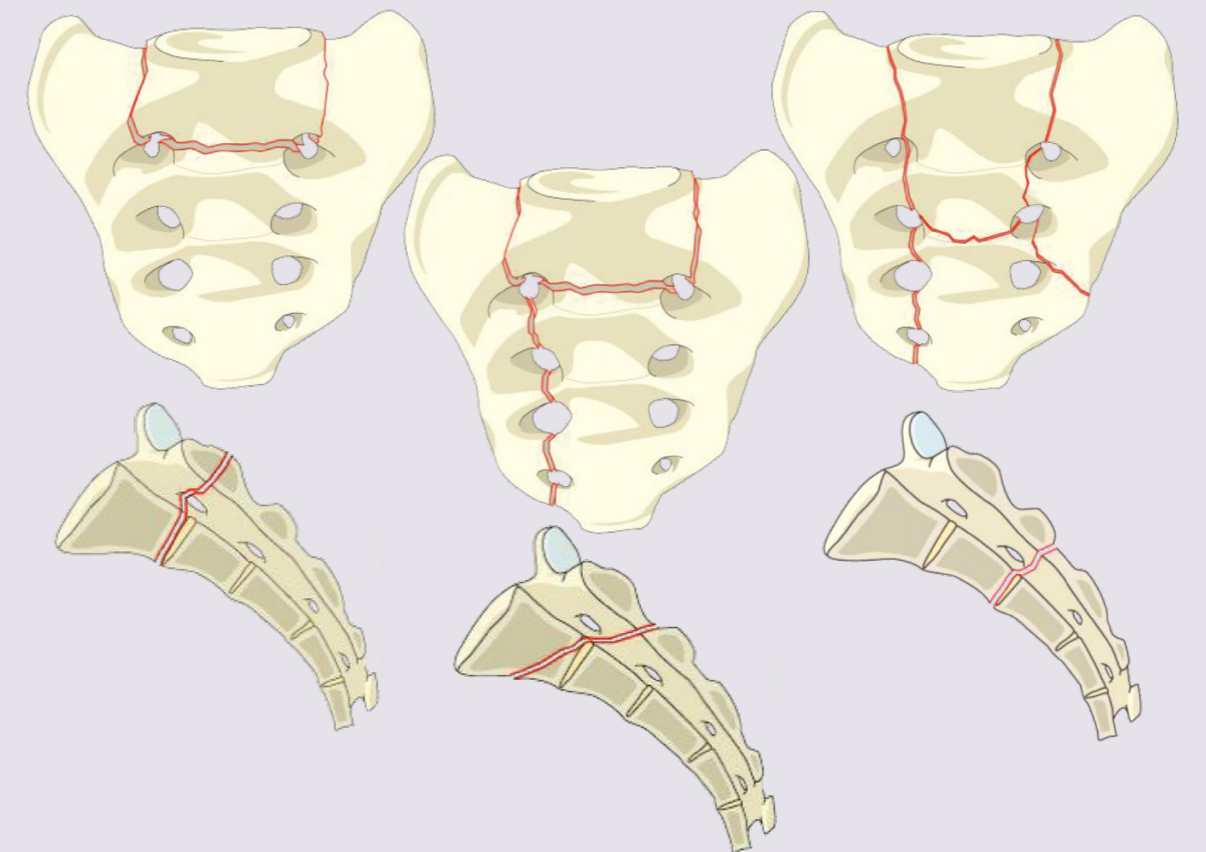
## Type C

### Spino-Pelvic Injuries

Spino-pelvic instability

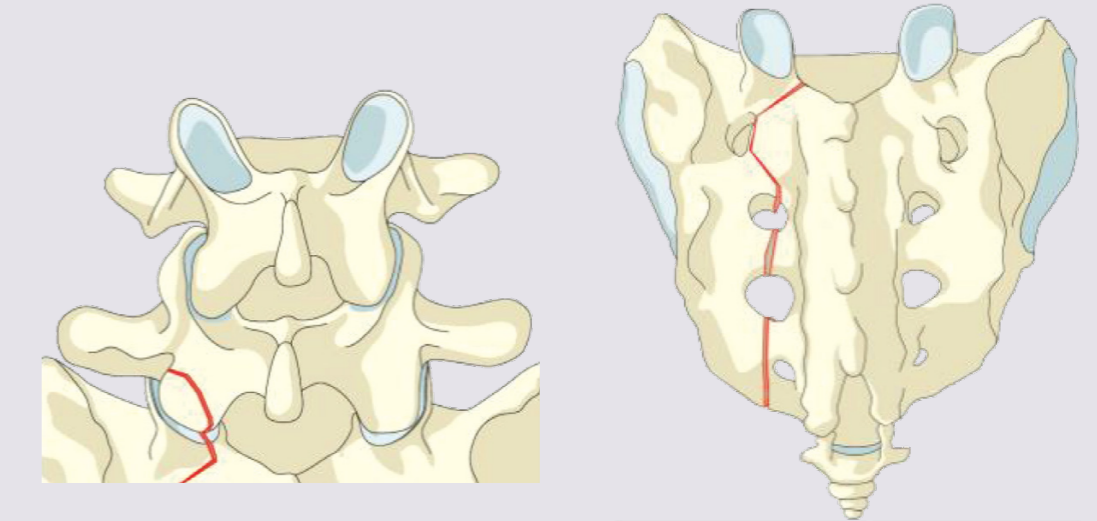
#### C0 Nondisplaced sacral U-type variant

- Commonly seen low-energy insufficiency fracture



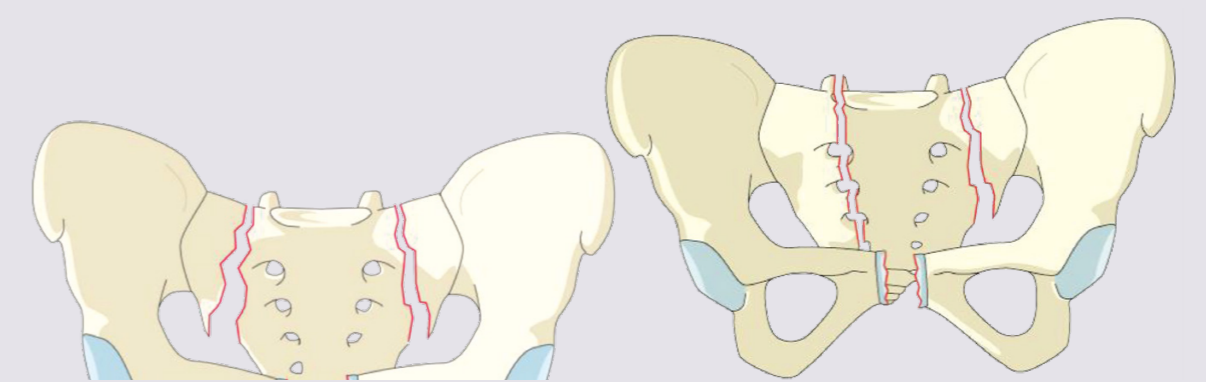
#### C1 Sacral U-type variant without posterior pelvic instability

- Any unilateral B-subtype where ipsilateral superior S1 facet is discontinuous with medial part of sacrum
- May impact spino-pelvic stability (Isler)



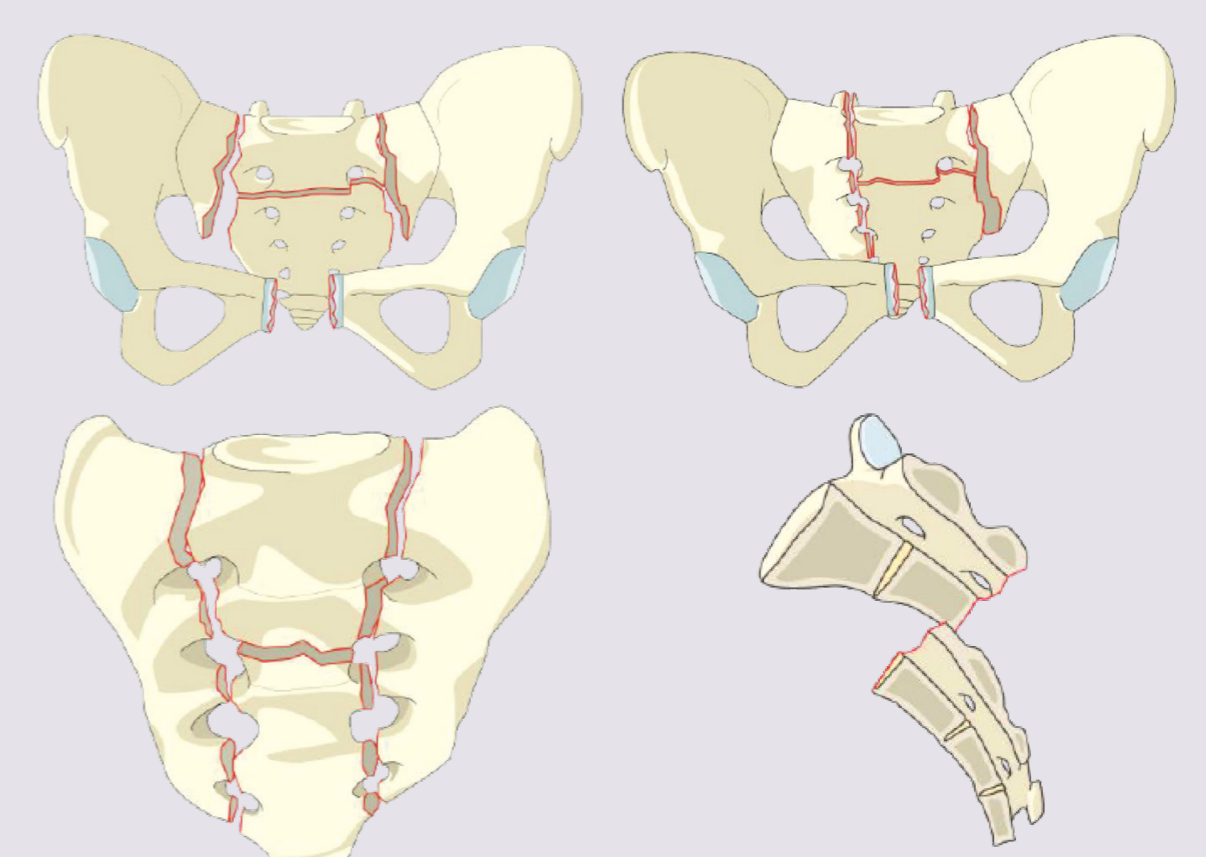
#### C2 Bilateral complete Type B injuries without transverse fracture

- More unstable and higher likelihood of neuro injury than C1



#### C3 Displaced U-type sacral fracture

- Worst combination of instability and likelihood of neuro injury
- Displaced transverse sacral fracture = canal compromise



### Sacral Fractures—Overview

Hierarchical system progressing from least to most unstable

- **Type A Lower Sacrococcygeal Injuries**  
No impact on posterior pelvic or spino-pelvic instability
- **Type B Posterior Pelvic Injuries**  
Primary impact is on posterior pelvic stability
- **Type C Spino-Pelvic Injuries**  
Spino-pelvic instability

### Neurology

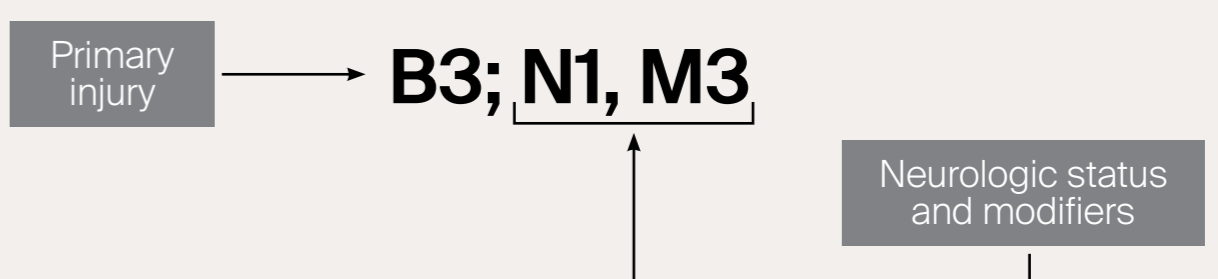
Type	Neurological
N0	Neurology intact
N1	Transient neurologic deficit
N2	Radicular symptoms
N3	Incomplete spinal cord injury or any degree of cauda equina injury
N4*	Complete spinal cord injury
NX	Cannot be examined
+	Continued spinal cord compression

### Modifiers

Type	Description
M1	Soft tissue injury
M2	Metabolic bone disease
M3	Anterior pelvic ring injury
M4	Sacroiliac joint injury

### Classification Nomenclature

Transforaminal fracture (B3) high energy injury associated with transient neurological deficit (N1) and anterior pelvic ring injury (M3)



\*The AO Spine Injury Classification Systems follow a universal neurological system for the whole spine. For the sacrum, N4 is theoretically and anatomically impossible.