

Expert Advice Forum of AOSpine International

“Management of Intraoperative Vertebral Artery Lacerations”

K. Daniel Riew (USA) 1
Jay S. Reidler (USA) 1
Edward Benzel (USA) 2
Atul Goel (India) 3
Luiz Vialle (Brazil) 4
Abumi Kuniyoshi (Japan) 5
Richard Assaker (France) 6
Yu Sun (China) 7
Jin Sup Yeom (Korea) 8
Rajasekaran Shanmuganathan (India) 9

1. NewYork-Presbyterian Och Spine Hospital, Columbia University Medical Center, New York, USA.
2. Cleveland Clinic Lerner College of Medicine, Cleveland, USA.
3. Department of Neurosurgery, K.E.M. Hospital and Seth G.S. Medical College, Parel, Mumbai, Maharashtra, India.
4. Department of Orthopaedic Surgery, Catholic University, Curitiba, Brazil.
5. Department of Orthopaedics, Sapporo Orthopaedic Hospital, Sapporo, Japan.
6. Department of Neurosurgery, Centre Hospitalier Régional Universitaire de Lille, Lille, France.
7. Department of Orthopaedic Surgery, Peking University Third Hospital, Beijing, China.
8. Spine Center and Department of Orthopaedic Surgery, Seoul National University College of Medicine, Seoul National University Bundang Hospital, Sungnam, South Korea.
9. Ganga Hospital, Coimbatore, Tamil Nadu, India

Introduction

Vertebral artery injuries are among the most feared complications in cervical spine surgery. While other catastrophic complications such as quadriplegia, profound neurologic deficits, or medical complications can be quite devastating to both the patient and the surgeon, a vertebral artery injury can actually result in intraoperative death of the patient. This can happen despite the best efforts of the surgeon if he/she is unable to get control of the bleeding and the patient exsanguinates. Blood loss associated with injuries has been reported to average several thousand milliliters and range to over 8500 milliliters.¹

For obvious reasons, there are no prospective randomized studies on this topic and few guidelines in the literature as to how to manage such an intraoperative catastrophic event. In this paper, expert cervical spine surgeons with extensive surgical experience taking care of cervical spine conditions developed a consensus opinion about how to manage intraoperative vertebral artery injuries. The paper is divided into two sections: anterior cervical spine injuries and posterior cervical spine injuries. In both scenarios, it is critical that the surgeon stay calm and not panic. This can be quite difficult if the surgeon is inexperienced or has never thought about the possibility of a vertebral artery injury. Therefore, we strongly recommend that every

surgeon performing cervical spine procedures prepare for the possibility of a vertebral artery injury and review the steps that need to be taken in the event that it occurs. In addition, we recommend that a small tray with microsurgical tools be kept on standby for all cervical cases. This tray should include temporary aneurysm clips, right angle hemostats, straight and curved Castroviejo needle drivers, micro right-angled ball-tipped probes, DeBakey micro forceps, 2- and 3-mm micro-suction tips, and vessel loops. Searching for these tools after an injury has occurred can result in excessive blood loss or even patient death, so it is recommended that several such kits be kept available at all times.

Avoidance of Vertebral Artery Injuries:

The best way to avoid vertebral artery injuries is to be aware that anomalous vertebral artery courses are common and take steps during the procedure to actively protect against such injuries. We recommend that for every cervical procedure, the surgeon closely examine the location of the vertebral artery on the preoperative magnetic resonance imaging (MRI) or computed tomography (CT). If there is any question, an MRI angiogram or a CT angiogram should be obtained. Any unusual vertebral artery anatomy should be noted such as an anomalous location, a bifid vertebral artery, a tortuous artery, or a unilateral artery (Figures 1-6). The side of the dominant vertebral artery should be noted preoperatively (Figure 2). During the procedure, the surgeon should regularly reconsider the vertebral artery anatomy and take appropriate precautions when operating in proximity to the artery. The surgeon should avoid pulling or pushing sharp instruments in a lateral direction, as this can cause accidental arterial injury. Rather, whenever possible, sharp instruments such as a curette or scalpel should be directed away from the artery. If it is necessary to use a sharp instrument towards an artery, one can place a barrier laterally to help prevent injury to the artery. For instance, a suction or a Penfield dissector can be placed laterally to block a laterally-directed curette from violating the artery (Figures 7-8).

When planning for procedures with high risk of vertebral artery injury (e.g., tumor involving the foramen transversarium), some members of this group request a preoperative angiogram with vertebral artery occlusion test. This can allow one to evaluate basilar artery blood flow following occlusion as well as the patient's clinical tolerance for such a change. If surgery will involve radical excision of a segment of the vertebral artery, preoperative permanent occlusion can be performed.

Anterior Vertebral Artery Injuries:

The vertebral artery can be injured in a number of different situations during anterior cervical procedures. First, the artery can be injured during the dissection of the longus colli muscle if it is anterior to the costal process of the foramen transversarium (Figures 1 and 3). The costal process is a thin piece of bone that constitutes the anterior roof of the foramen transversarium. Second, it can be injured lateral to the uncovertebral joints during lateral dissection. Third, it can be injured during a foraminotomy or uncinectomy. Finally, it can be injured during a corpectomy if the surgeon violates the lateral wall of the vertebral body or if the artery enters the vertebral body with aberrant anatomy. These types of injuries are best avoided by remaining aware of the vertebral artery location on the preoperative imaging and by avoiding disorientation during the exposure and main procedure.

If the artery has been injured, the sequence of steps to follow include 1) rapid compression and tamponade, 2) mobilization and visualization, and 3) repair or ligation. The immediate reaction following recognition of a vertebral artery injury should be instantaneous placement of

the surgeon's index finger on the bleeding focus before visualization is lost. If the anatomy does not allow tamponade with a finger, patties can be used. In certain cases, Surgicel (Ethicon) can be packed into the cranial and caudal foramen transversarium to stop blood flow. Anesthesia should be immediately informed of the injury, the potential need for fluid resuscitation, and the importance of maintaining cerebral perfusion pressure. If the artery has been injured during the approach, it is likely the arterial injury occurred anterior to the foramen transversarium. By applying direct pressure with a finger or patties, one can usually get the bleeding to stop. Hemostatic agents can be used to help as well, but the surgeon should be careful to avoid embolization of them through the arterial tear. Two large-bore suckers at full suction may be necessary to evacuate blood for proper visualization. Avoid monopolar electrocautery as a means to control bleeding since this may worsen the arterial injury.

In some cases, such as in complete arterial lacerations, part of the artery may retract into the foramen transversarium and may not be accessible to direct compression. If this is the case, the artery needs to be exposed. Since the artery lies in the foramen transversarium, the easiest way to expose it is to remove the costal process. A small curette can be used to free soft tissues from the undersurface of the process. It can then be unroofed with a 2-mm Kerrison rongeur or a small curette. After unroofing the costal process, one can directly compress the artery in the foramen transversarium. Furthermore, by unroofing the costal process above and below the area of injury, one can mobilize the artery and inspect it. A right angle hemostat can be used to reach under the artery and a vessel loop can be placed around the artery. By wrapping a vessel loop 360 degrees around the artery both cranial and caudal to the injury and lifting it ventrally, one can completely control the bleeding to inspect the artery. Temporary aneurysm clips can also be placed proximal and distal to the arterial tear for control. We recommend controlling the cranial end first to help minimize loss of blood from the brain. Please see Figures 9-10.

If the artery is injured when burring the lateral vertebral wall, the surgeon should be able to tamponade the source of bleeding relatively easily by compressing the defect in the lateral wall. Following an arterial injury, however, profuse bleeding can make visualization difficult and the surgeon may not be able to identify the origin of the bleeding. A panicking surgeon may erroneously apply posterior pressure onto the spinal cord while attempting to achieve hemostasis, causing neurologic injury and compounding the already catastrophic injury associated with vertebral artery laceration. The key is to tamponade laterally into the vertebral wall and not posteriorly into the spinal cord or into the neural foramen. Likewise, if the artery is injured during an uncinectomy, the surgeon should compress laterally and not posteriorly. Once the bleeding has been controlled, the artery should be mobilized for inspection as outlined above.

If there is a small arterial laceration, the artery can often be repaired with 6-0 or 7-0 proline sutures. If there is a large tear or complete transection, the surgeon should consider the options of repairing it or ligating it. Several steps can guide this decision. First, the surgeon can review imaging to see if the artery is the dominant or non-dominant vertebral artery. Second, the surgeon can check for backflow from the cranial side of the artery. Good backflow suggests good collateral circulation through the circle of Willis. If the contralateral side is the dominant artery and there is good backflow from the cranial side of the torn artery, then ligating the torn artery is less likely to result in neurologic deficits. It can be performed with multiple vessel clips or sutures applied above and below the laceration (Figure 11). Ligation should only be performed as a last resort given the risk of stroke, permanent neurologic injury, and even death. However, ligation is acceptable when repair options are unavailable, as ligation does not result in the above complications in the majority of patients.

Interventional radiology (IR) and vascular surgery should be consulted as soon as possible, since both teams can help guide decision making and treatment. Since the patient is supine, the groin can be prepped and draped, and IR can perform an angiogram through the femoral artery (Figure 12). If there is an incomplete transection, they may also be able to stent the artery. When an open repair is needed, vascular surgery can perform this or check the adequacy of repair if already completed by the spine surgeon. One expert in our group (J.S.Y.) operates in a center with relatively easy access to endovascular care and says that surgeons at his center have opted to proceed with stenting by default, since they have observed significantly less blood loss with this approach compared to either open repair or ligation.

If arterial injury occurs during an operation performed in an ambulatory surgery center, such intraoperative consultation may be impossible, thus limiting the surgeon's options to immediate repair or ligation. If available, the surgeon can consider placing temporary aneurysmal clips cranial and caudal to the arterial tear, and then transferring by ambulance to a hospital setting with vascular surgery and IR available for consultation. It is critical to confirm secure placement of the clips if this is to be done.

Vertebral artery injury does not necessarily mean that the procedure must be terminated. Depending on the stage of the procedure and the specific circumstances following injury, it may be acceptable to complete the procedure. For instance, if a repair is performed or even if bleeding is just temporarily controlled, it may be appropriate to complete the steps of an anterior cervical discectomy and fusion (ACDF) procedure prior to leaving the operating room.

After vertebral artery repair or stenting, the patient is usually placed on an anticoagulant such as clopidogrel and/or aspirin. Such agents can cause the wound to bleed and may result in an epidural or retropharyngeal hematoma. Therefore, prior to closure, all tissue surfaces should be inspected for active bleeding and meticulous hemostasis should be achieved. At the end of an anterior procedure, hemostatic materials such as Surgicel may be placed beneath the longus coli muscle, wrapped around the edges and ventral surface where there are many small blood vessels. Bone wax may be applied to the anterior surface of the vertebrae and thrombin-soaked demineralized bone matrix may be applied to bleeding endplates. A deep drain should be placed.

Posterior Vertebral Artery Injuries:

For posterior cervical approaches, there are several areas where vertebral artery injuries most commonly occur. 1) Subaxial vertebral artery injuries typically occur during placement of lateral mass or pedicle screws. In these cases, bleeding can usually be stopped by placing a short screw into the bleeding cortical hole. 2) For injuries between C1 and C2, the artery is not typically amenable to exposure because it is too far anterior and lateral. One can tamponade that area until the bleeding stops. 3) If the artery has been injured above the C1 arch, it can usually be mobilized and inspected once the bleeding has been controlled. Because the artery becomes intradural at the level of the foramen magnum, however, control may be difficult to achieve. 4) Anomalous vertebral arteries can present as persistent intersegmental arteries between C1 and C2. If the surgeon is not aware that such an artery exists, he or she may accidentally injure it while performing C1-2 procedures. For instance, such intersegmental arteries would be at risk during dissection in this area, decortication of the C1-2 joint, and during the deliberate transection of C2 nerve roots (Figure 5; also see Figure 6 for the ponticulus posticus anatomic variant).

Surgeons should maintain a high index of suspicion for occult vertebral artery injuries when operating in close proximity to the artery. One member of this group (Y.S.) reported a case of rapid onset quadriplegia 40 days after posterior cervical surgery caused by a pseudoaneurysm from an occult vertebral artery injury (Figure 13).² In retrospect, injury to the artery was believed to have occurred during drilling of the posterior ring of C1. While no severe intraoperative bleeding occurred, gelatin sponges successfully controlled bleeding that occurred around the site of injury and no arterial injury had been suspected. We therefore recommend that there be a low threshold for postoperative angiographic evaluation of the vertebral artery if there is any suspicious bleeding when operating in injury-prone vicinities.

As described for anterior injuries, if the artery has been injured during a posterior approach, the sequence of steps to control the bleeding include 1) rapid compression and tamponade, 2) mobilization and visualization, and 3) repair or ligation. If one artery has been injured previously or is injured during the current surgery, it is essential that the remaining artery not be further compromised, which could result in severe neurologic injury (Figure 14). For instance, such circumstances may involve aborting placement of the contralateral transarticular screw following ipsilateral arterial injury during C1-2 transarticular screw placement. Alternative techniques for obtaining fixation should be attempted that do not risk the intact vertebral artery. (Note: For C1 and C2 screws, we recommend starting screw placement on the non-dominant vertebral artery side).

Postoperatively, mean arterial blood pressures should be kept above 90 so as to maximize cerebral perfusion. As with every arterial injury or suspected injury, the surgeon should obtain a vascular study such as an angiogram, MRI angiogram, or CT angiogram to assess the artery and determine the need for further intervention. This should be done in concert with the vascular team. If neurologic deficits are noted, the neurological stroke team should be consulted to assess for additional treatment options.

It is important that the surgeon speak to the patient and family with full transparency about the arterial injury as they guide them through the postoperative recovery. If the patient should ever need another cervical procedure, both the patient and surgeon need to know that there is only one functioning vertebral artery.

Tips and Tricks

- Prepare for the possibility of a vertebral artery injury by reviewing the steps that need to be taken if it occurs.
- Confirm that the tools and consulting teams needed for managing such injuries are available at your institution. Have a microsurgical toolset on standby for all cervical cases.
- For every operative cervical procedure, closely examine the vertebral artery anatomy on preoperative MRI/CT and obtain vascular imaging as needed for clarification.
- Avoid pulling or pushing sharp instruments in a lateral direction toward the artery.
- Obtain postoperative angiography if you suspect that an occult vertebral artery injury occurred during surgery.
- For C1 and C2 screws, start your screw placement on the non-dominant vertebral artery side.

If an Intraoperative Vertebral Artery Injury Occurs...

- If the anatomy allows, rapidly compress the artery with your index finger before visualization is lost. Alternatively, tamponade the artery with patties.
- Immediately inform anesthesia of the injury. Tell anesthesia about the potential need for fluid resuscitation and the importance of maintaining cerebral perfusion pressure.
- Ask your staff to request intraoperative consultation by interventional radiology and/or vascular surgery.
- Keep yourself and your staff calm.
- Have your assistant use two large-bore suckers to help maintain visualization.
- For injuries between the foramen transversarium during anterior approaches, mobilize and visualize the artery by removing the costal processes with a 2-mm Kerrison rongeur.
- Place vessel loops or aneurysm clips around the cranial and caudal ends of the artery to help control bleeding.
- In concert with the IR/vascular teams, decide between open repair, endovascular stenting, and ligation. Intraoperative angiography may help with this decision-making.
- Depending on the specific circumstances, it may be acceptable to complete the intended procedure after or before the arterial laceration treatment.
- If the injury occurs during screw preparation/placement, place a short screw into the bleeding cortical hole and obtain angiography intra- or post-operatively to further evaluate the injury.
- Place a deep drain at the end of the procedure.
- Place the patient on anticoagulation and obtain postoperative angiography as recommended by the IR/vascular teams.
- Keep mean arterial blood pressures above 90 mmHg postoperatively in order to maximize cerebral perfusion.
- If neurologic deficits are noted, consult the neurological stroke team to assess for additional treatment options.
- Speak to the patient and family with full transparency about the arterial injury as you guide them through the postoperative recovery.

- Do NOT apply pressure onto the spinal cord while attempting to achieve hemostasis. This may cause neurologic injury and compound the already major injury associated with the vertebral artery laceration.
- Do NOT use monopolar electrocautery to control the bleeding. This may worsen the injury.
- Do NOT inject hemostatic agents directly into the arterial laceration. These can embolize to the brain and result in neurologic injury.
- Do NOT use screw trajectories that risk the remaining intact vertebral artery after one artery has been injured.

Conclusion

Surgeons must be familiar with the steps for managing an intraoperative vertebral artery laceration. Microsurgical tools should be readily accessible during cervical procedures. To avoid vertebral artery injury, carefully examine the location of the vertebral artery on the preoperative MRI or CT, and regularly consider this anatomy and any anomalies during the procedure. Avoid pulling or pushing sharp instruments in a lateral direction toward the artery. If the artery is injured, the sequence of steps to follow include 1) rapid compression and tamponade, 2) mobilization and visualization, and 3) repair or ligation. The first step should be instantaneous placement of the surgeon's index finger, or patties, on the bleeding focus before visualization is lost. Tamponade laterally into the vertebral wall and not posteriorly into the spinal cord or into the neural foramen, as this can cause neurological injury. Interventional radiology and vascular surgery should be consulted as soon as possible. It may be acceptable to complete the cervical spine procedure. Before closure, all tissue surfaces should be inspected for active bleeding and meticulous hemostasis should be achieved. For every arterial injury or suspicious bleeding, a vascular study should be completed to assess the artery and determine the need for further intervention.

Figures:

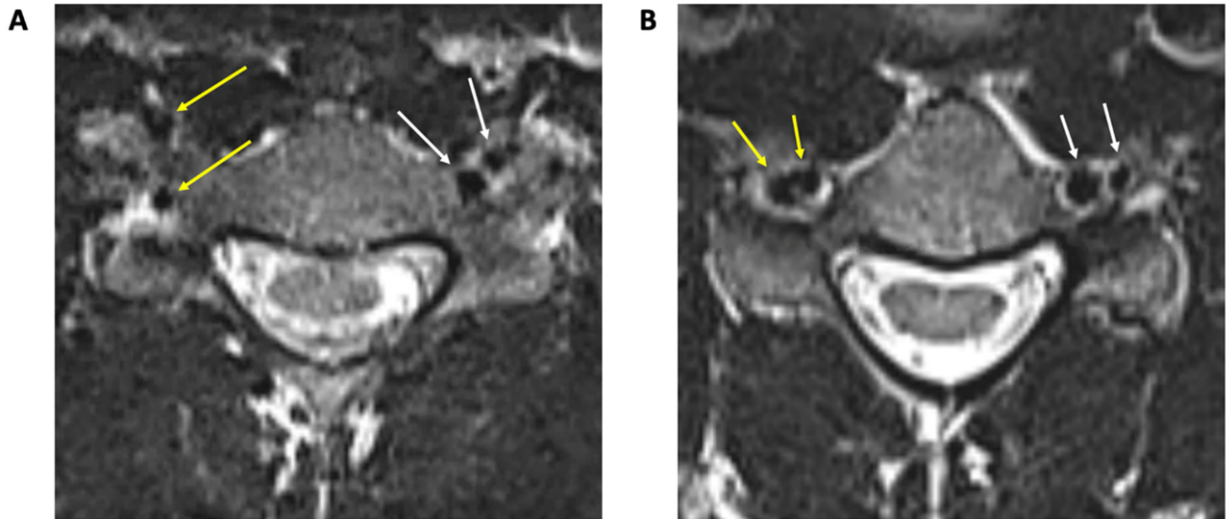


Figure 1. Vertebral artery variants detected on MRI. A. At C6, there is one right vertebral artery branch anterior to the foramen transversarium and one branch inside it (yellow arrows). There are two left vertebral artery branches within the foramen transversarium (white arrows). B. At C4, both sides have the two branches within the foramen.

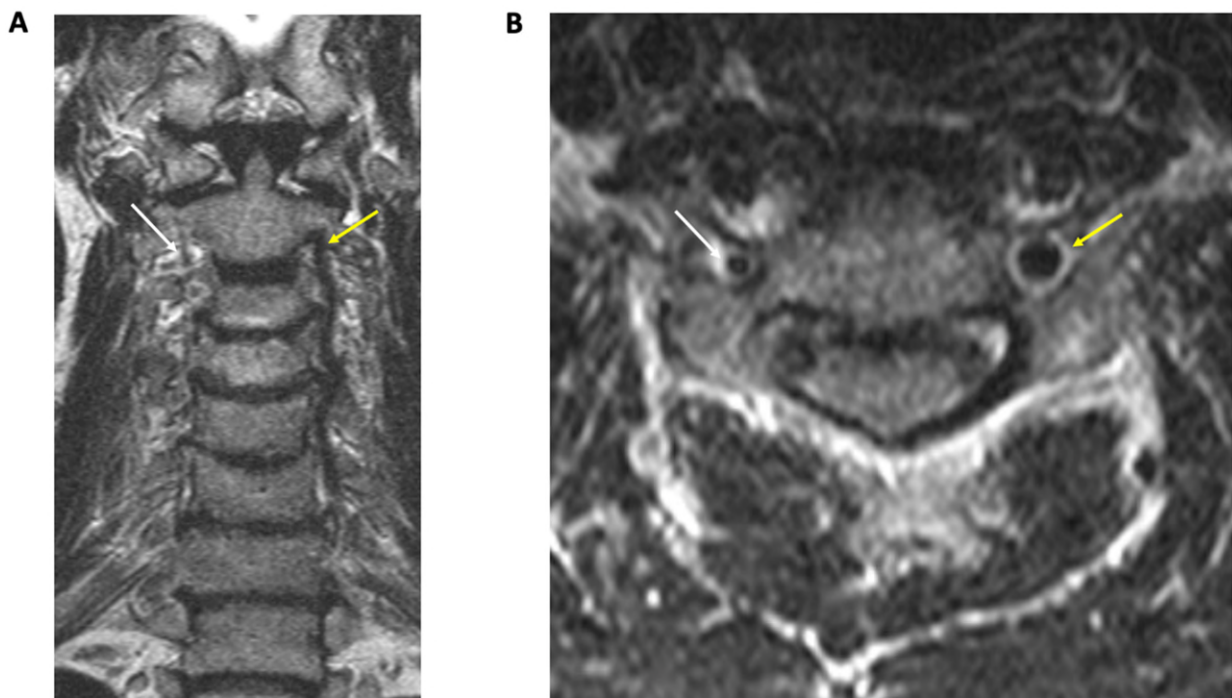


Figure 2. MRI showing a dominant left-sided vertebral artery (yellow arrows) and a non-dominant right-sided vertebral artery (white arrows).

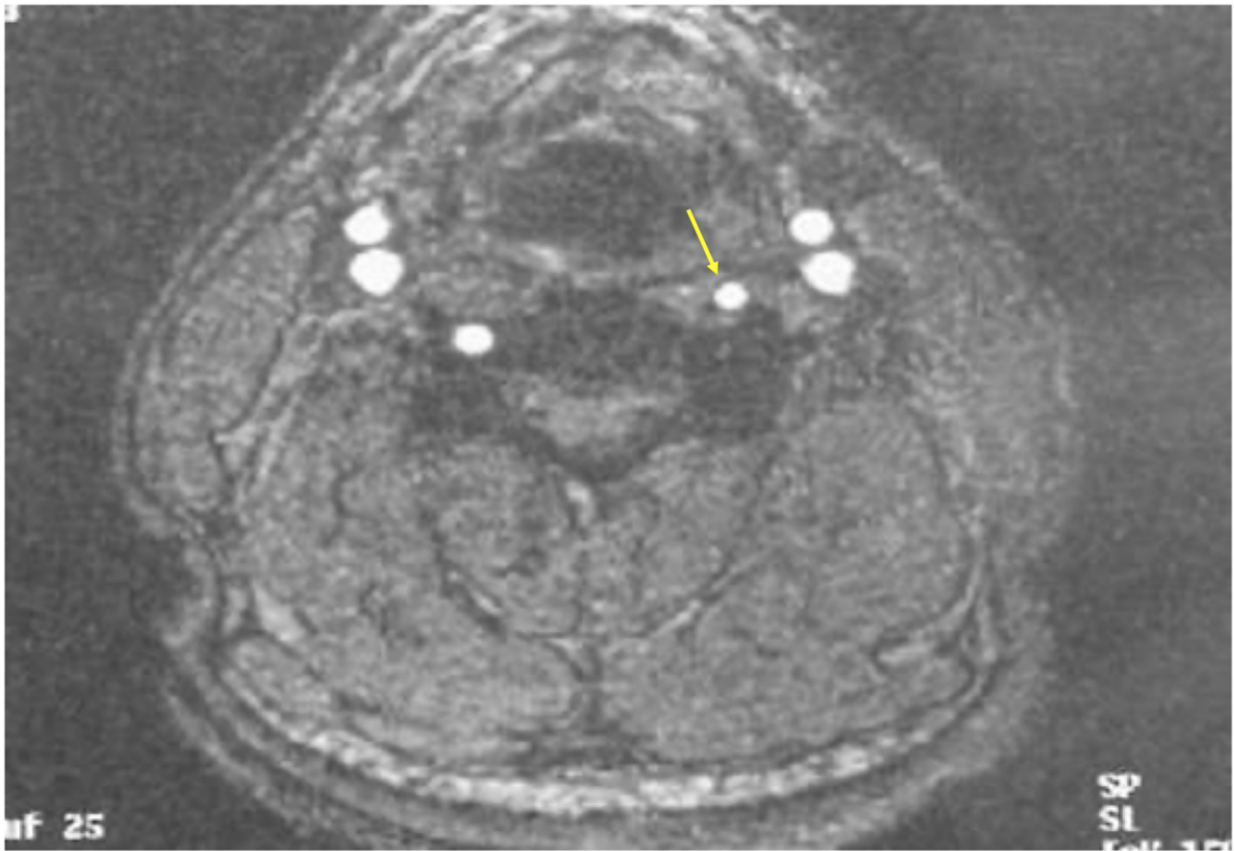


Figure 3. MRA showing the left vertebral artery anterior to the foramen transversarium (yellow arrow).

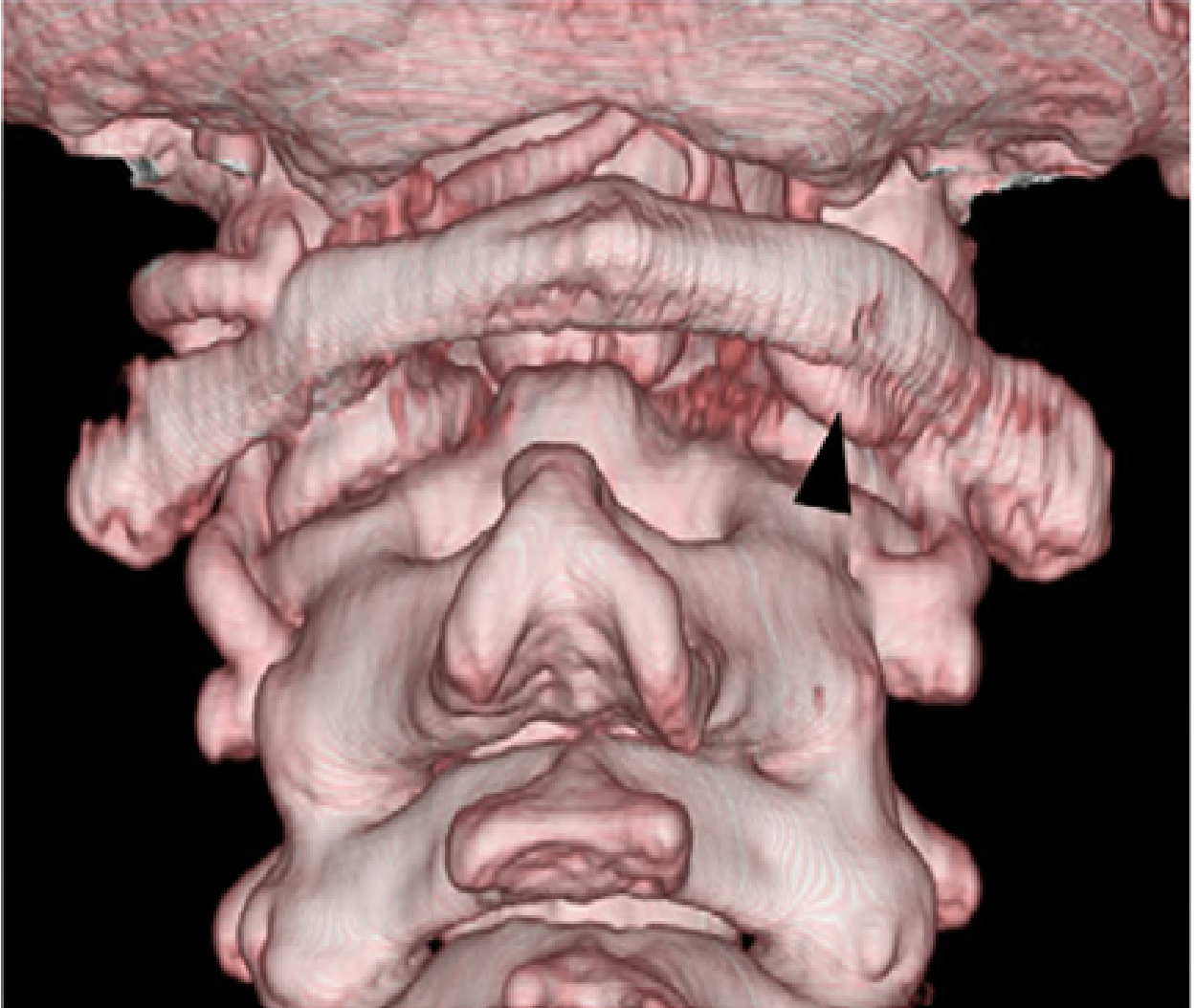


Figure 4. CTA demonstrates an anomalous vertebral artery (black arrow) that travels under the C1 arch.

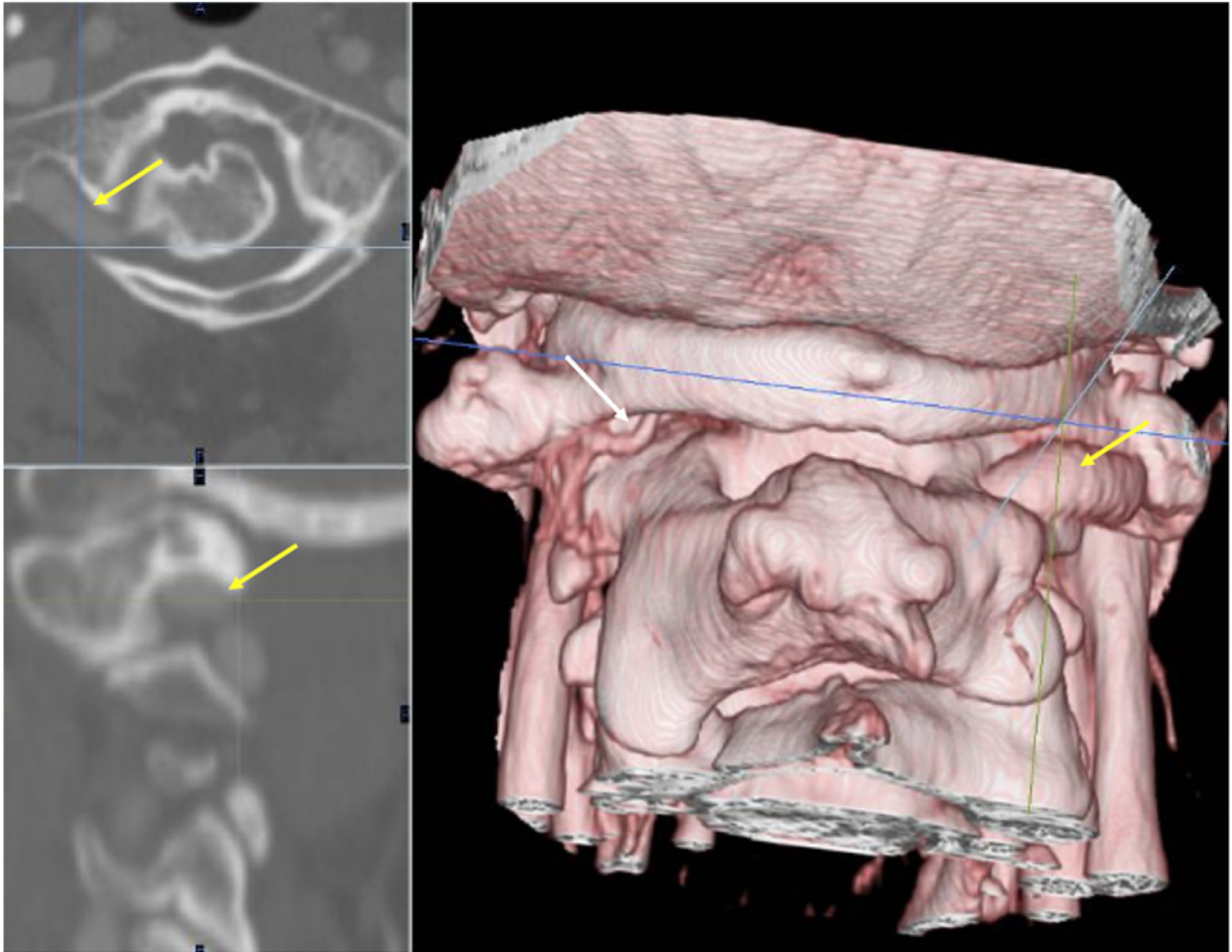
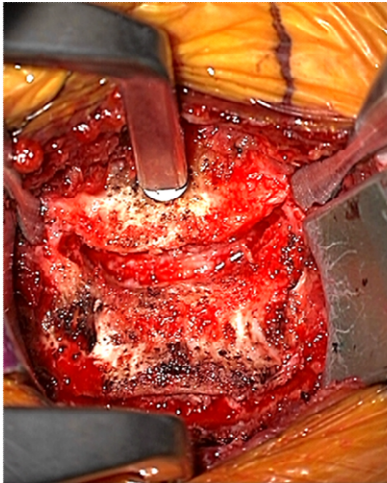


Figure 5. CTA showing a right dominant intersegmental artery (yellow arrows) with small left intersegmental artery (white arrow).

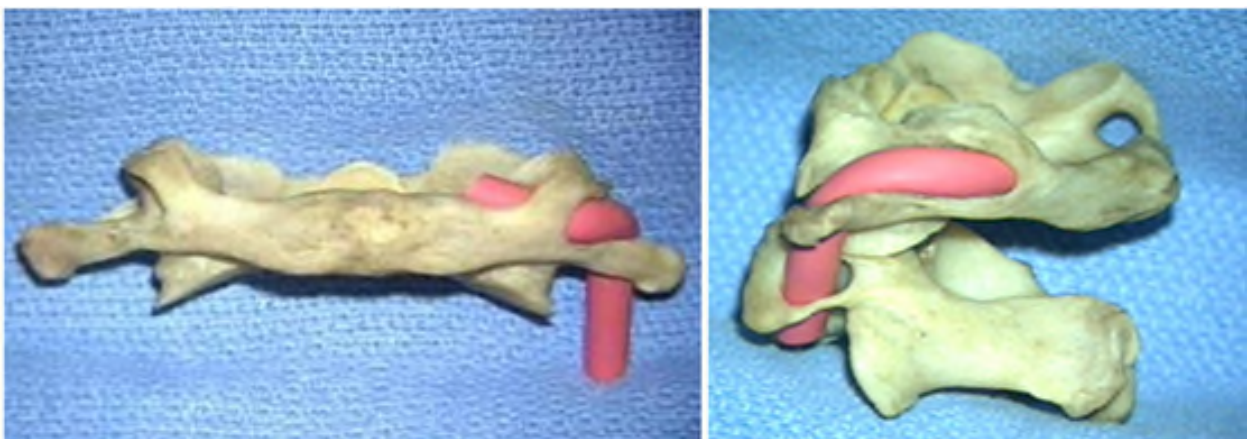

Figure 6. A ponticulus posticus is a bony bridge between the posterior arch and the lateral mass of the atlas that encircles the vertebral artery. A widened posterior C1 arch may look like a convenient place to place a C1 arch screw, but it is important to recognize that the artery may lie in the intended trajectory.

A



B

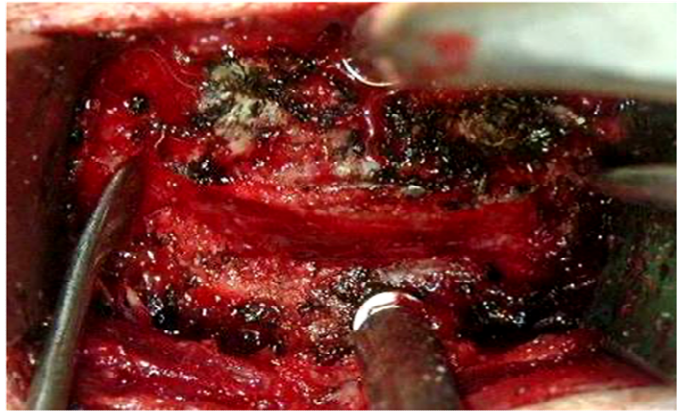


Figure 7. When performing an uncinectomy, a Penfield dissector can be placed laterally to protect the vertebral artery. A. Penfield protecting the left vertebral artery. B. Penfield protecting the right vertebral artery.

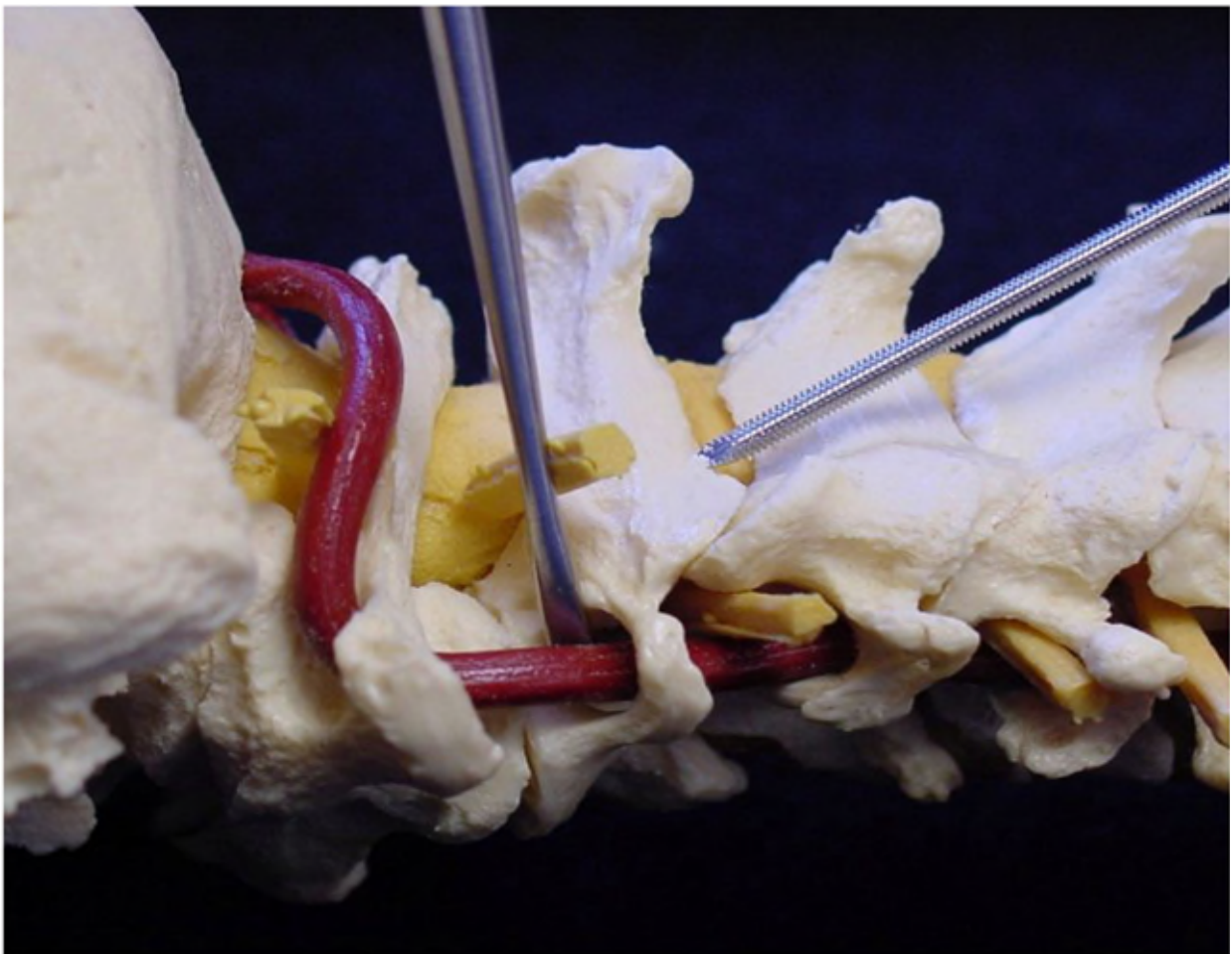


Figure 8. During transarticular screw fixation, a Penfield 4 dissector or curette can demarcate the location of the artery.

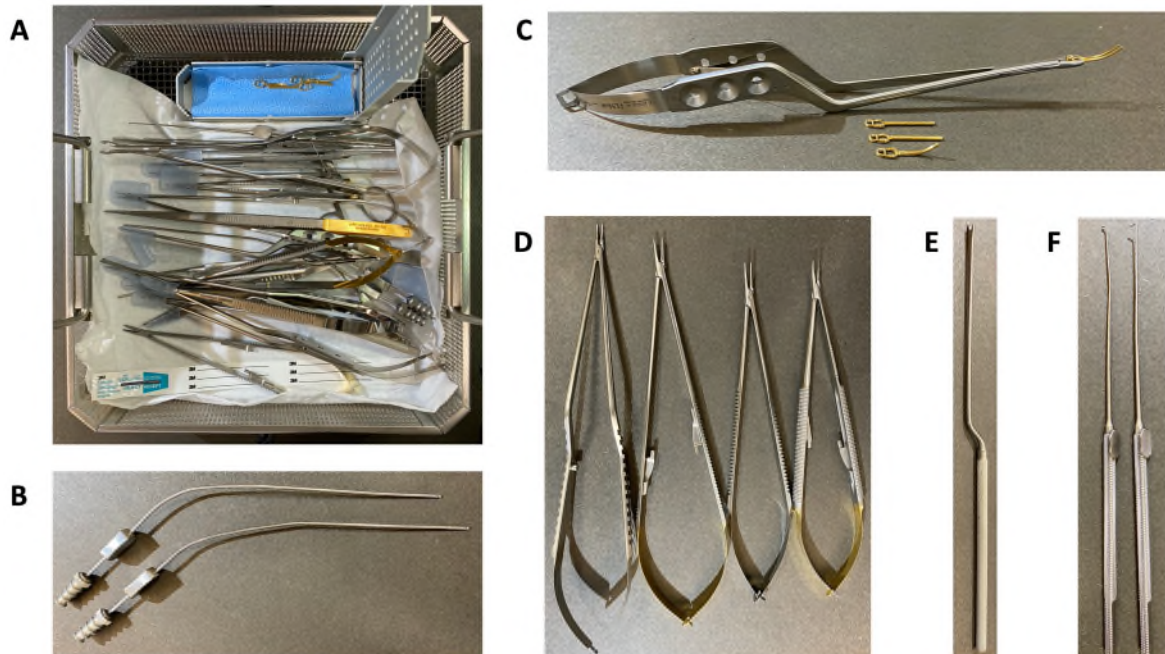


Figure 9. Microsurgical toolset on standby for all cervical cases. A. Microsurgical tray B. Microsuckers C. Aneurysm clips and clip holder D. Castroviejo needle holders E. Micro knot pusher F. Micro ball-tipped probes

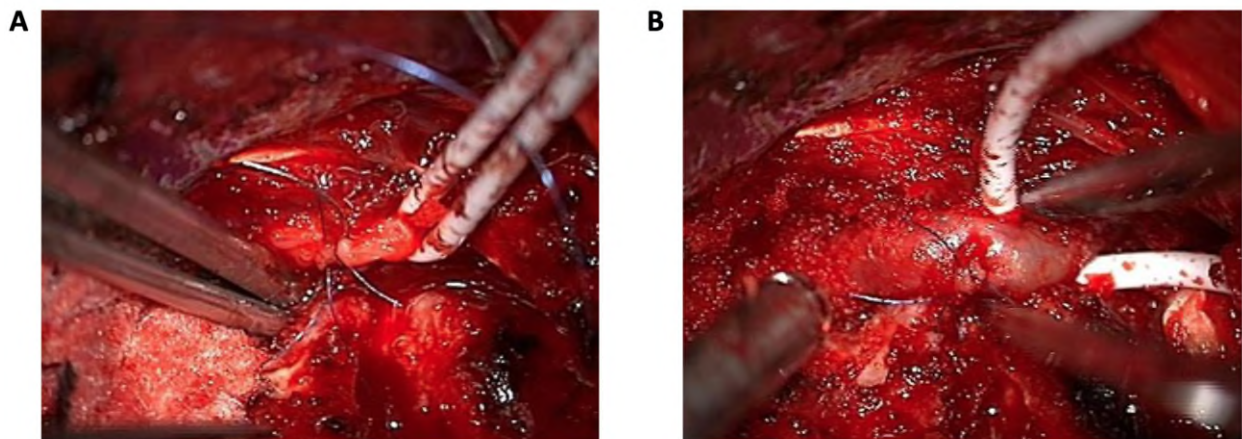


Figure 10. Vertebral artery injury repair. A. A vessel loop helps to control the artery during the repair. B. Arterial flow with the vessel loop relaxed.

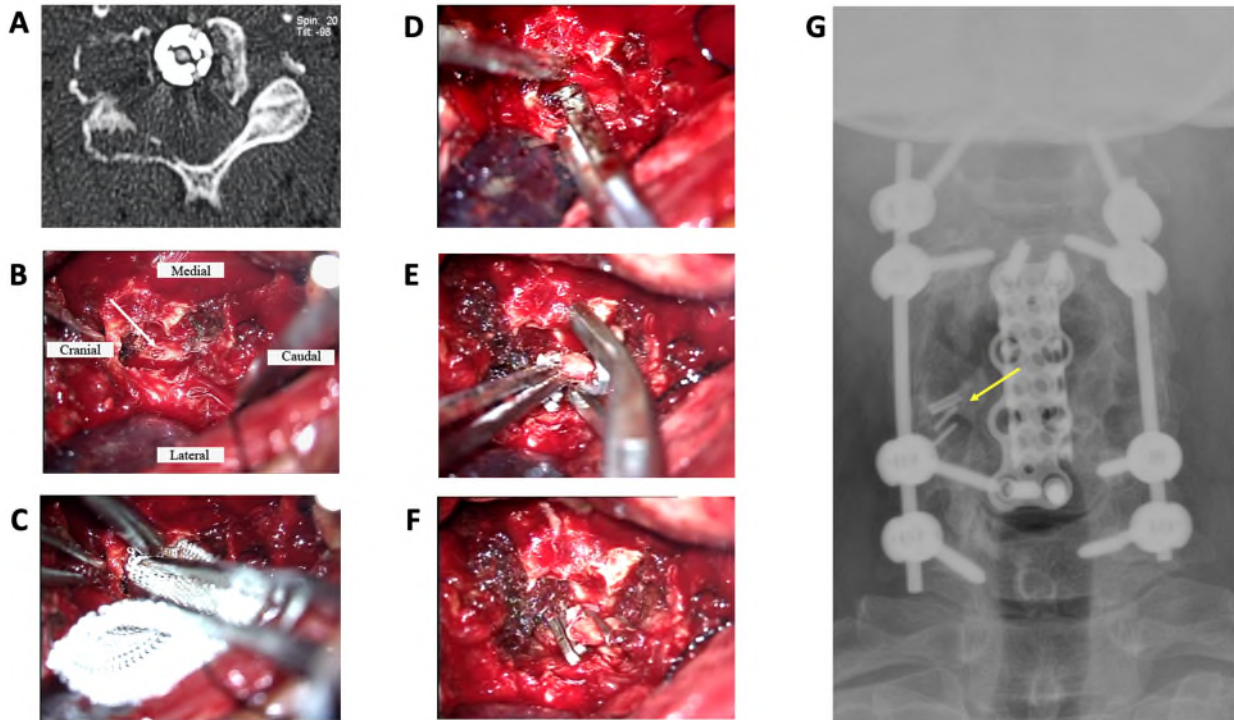


Figure 11. Case of vertebral artery injury during anterior surgery for recurrent giant cell tumor. A. CT showing right-sided lytic lesion that extends from the right vertebral body into the foramen transversarium. B. During anterior dissection of the tumor there was a bright red gush of blood from a tear (white arrow) in the vertebral artery. C. Temporary hemostasis was achieved by packing Surgicel into the cranial and caudal foramen transversarium. D. Vertebral artery exposure was improved by using the Kerrison punch to remove the costal process of the foramen transversarium near the tear. E-F. After confirmation that the contralateral artery was intact, ligation was performed by application of vascular clips cranially and caudally to the tear. G. Postoperative radiographs demonstrate 2 vessel clips placed on both sides of the tear (yellow arrow).

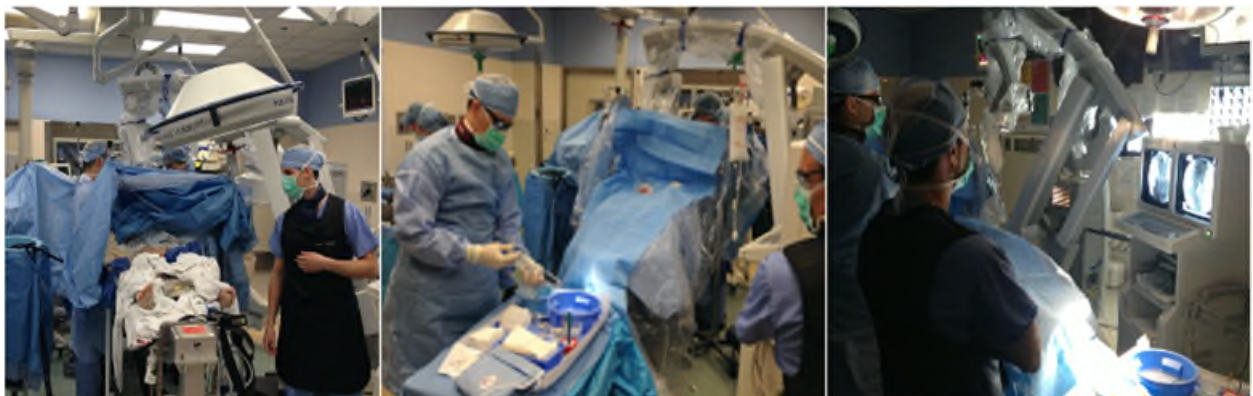

Figure 12. Interventional radiology performing an intraoperative angiogram through the femoral artery in an ACDF patient with a vertebral artery injury. The distal drape is lifted and the thigh is prepped and draped for the angiogram. Note that the spine surgeons are still scrubbed in and able to operate in the anterior cervical surgical field, which remains sterile.

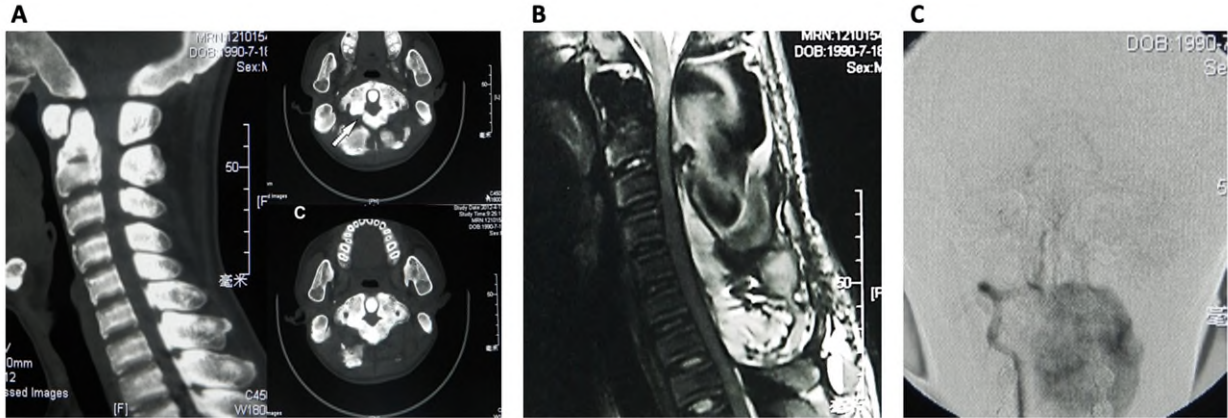


Figure 13. Delayed presentation of a vertebral artery injury. A. A 21-year-old man with skeletal fluorosis and cervical myelopathy underwent decompression of C1 to C7 and instrumentation from C2 to C7. The pre-OP CT scan showed abnormal vertebral artery groove anatomy (white arrow). No severe bleeding occurred. B. On postoperative day 40, the patient developed quadriplegia and was found to have a large epidural hematoma with severe cord compression. C. Angiography demonstrated evidence of pseudoaneurysm of the right V3 segment in the vertebral artery groove of the atlas. In retrospect, the artery was believed to have occurred during drilling of the posterior ring of C1. Gelatin sponges were used to obtain hemostasis and no arterial injury had been suspected. (Image excerpted from Reference 2)

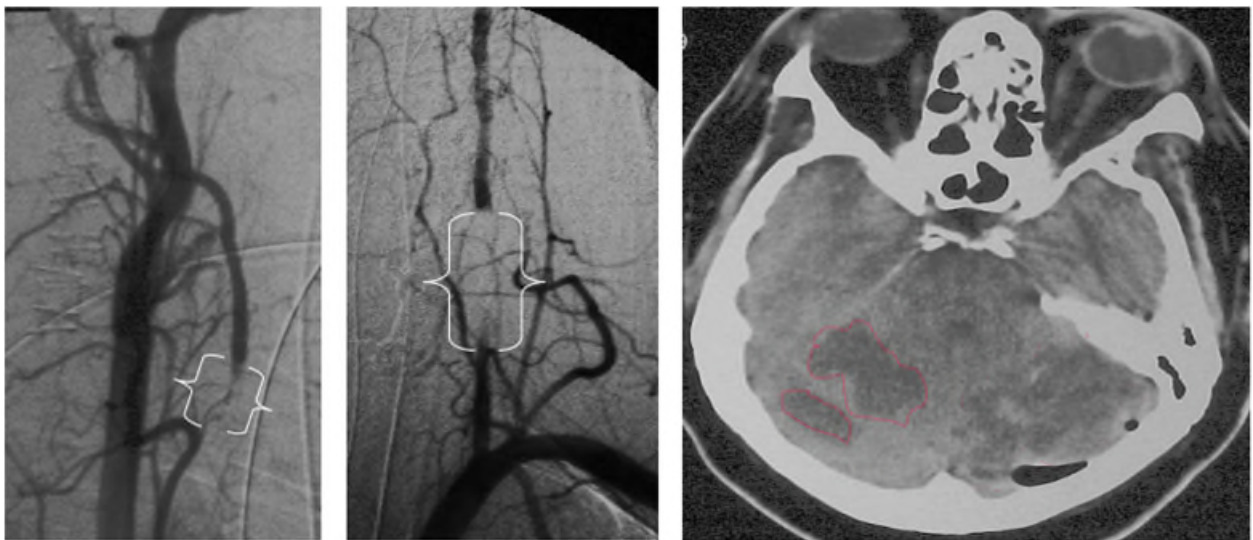


Figure 14. Bilateral vertebral artery injuries resulting in a cerebellar stroke.

References

1. Neo M, Fujibayashi S, Miyata M, Takemoto M, Nakamura T. Vertebral artery injury during cervical spine surgery: a survey of more than 5600 operations. *Spine (Phila Pa 1976)*. 2008 Apr 1;33(7):779-85. doi: 10.1097/BRS.0b013e31816957a7.
2. Diao Y, Sun Y, Wang S, Zhang F, Pan S, Liu Z. Delayed epidural pseudoaneurysm following cervical laminectomy and instrumentation in a patient with canal stenosis secondary to skeletal fluorosis: A case report. *Medicine*. 2018 Feb; 97(8):e9883.