

Forearm fractures

Volker Braunstein

Disclaimer

All contents of this study guide are owned by AO Foundation/AO Trauma and cannot be used for any other than private purposes. This work may only be used for your private education.

How to use this handout?

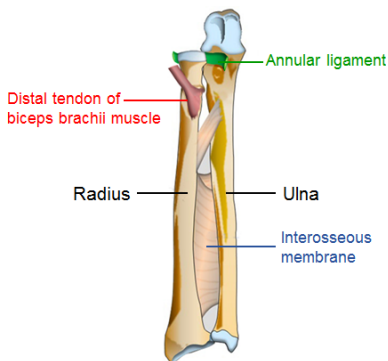
The left column is the information as given during the lecture. The column at the right gives you space to make personal notes.

Learning outcomes

At the end of this lecture you will be able to:

- Outline the anatomy and physiology of the forearm
- Outline indications for nonoperative and operative treatment
- Discuss principles of surgical treatment

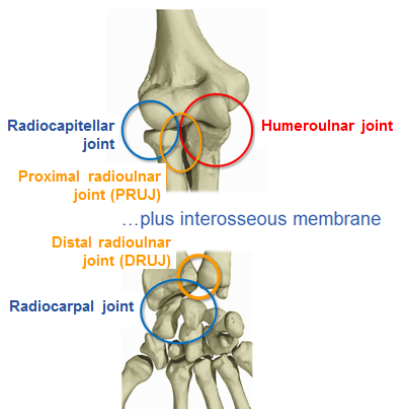
Anatomy of the forearm



The interosseous membrane of the forearm is a fibrous sheet, spanning the interval between the radius and the ulna, which divides the forearm into anterior and posterior compartments. It serves as a site of origin of the forearm muscles, and transfers forces from the radius to the ulna.

The annular ligament

encircles approximately 80% of the head of the radial head and retains it in its anatomical relationship at the proximal radioulnar joint.



The forearm bones articulate with the humerus at the humeroulnar and radiocapitellar joints. It is at these joints that flexion and extension of the elbow occur.

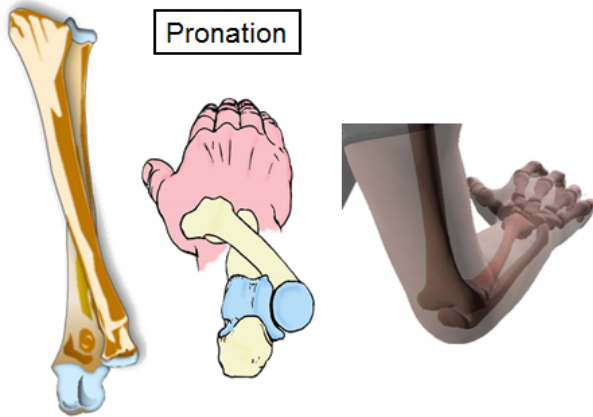
The articulations between the radius and ulna permit pronation and supination. These comprise the proximal and distal radioulnar joints.

The radiocarpal articulation allows wrist flexion, extension, and both radial and ulnar deviation.

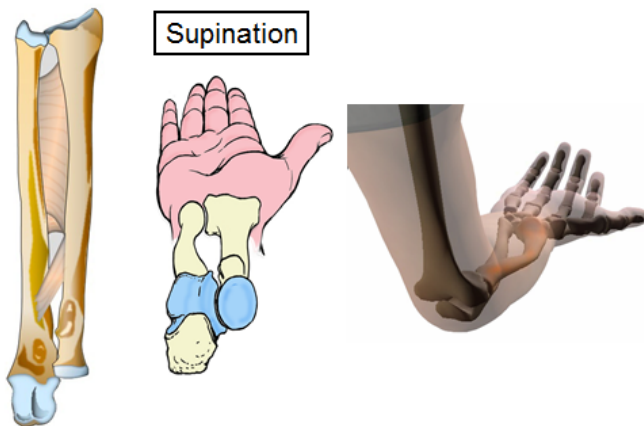
Supination and pronation

Supination and pronation is easily confused with medial and lateral rotation but the difference is that pronation and supination can occur only when the forearm is semiflexed.

- **Pronation** moves the palm of the hand so that it is facing posteriorly (*your forearms are pronated when typing on a keyboard*).



- **Supination** moves the palm of the hand so that it is facing anteriorly (*your hands are supinated when holding a bowl of soup*).



The forearm bones and their rotational articulations function as a single joint.

For this reason, the objectives of treatment of all joint fractures apply:

- Anatomical reduction
- Stable fixation
- Early functional aftercare

Forearm fractures

Epidemiology

10–14% of all fractures occur in the forearm. The incidence of forearm shaft fractures does not increase with age.



The fracture mechanism is often high-energy trauma, resulting in:

- Axial compression
- Bending
- Rotation
- Direct trauma

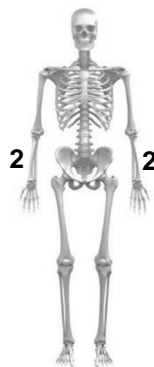
Radiological investigations

- X-ray—In two planes (including both radio-ulnar joints)
- CT—Rarely indicated
- MRI—To be done occasionally, mainly to identify suspected articular cartilage or ligament damage

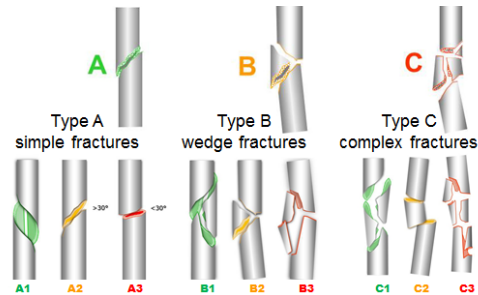
AO/OTA Fracture classification

Forearm shaft fractures=22

1. Bone=2



2. Segment=2

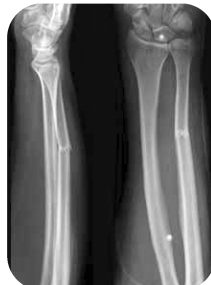

Treatment

Nonoperative

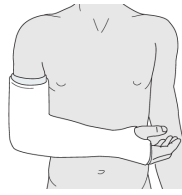
1. Indications

- Fractures without displacement and without associated dislocation
- Patients in poor general condition with high surgical risks



2. Treatment

- Cast for minimum 4 weeks— including adjacent joints
 - Fractures in proximal forearm, cast in supination. A cast in supination position will reduce the displacing forces of supinator and biceps brachii muscles.
 - Fractures in middle or distal part, cast in neutral rotation
- X-ray controls—frequently, ideally weekly to show fracture position.



3. Risks

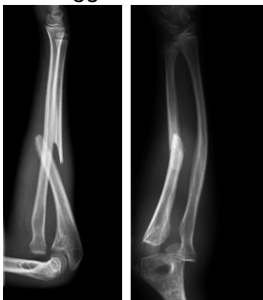- Chance of delayed or nonunion is up to 30%.
- Limited range of motion (ROM) after immobilization
 - Pronation, supination
 - Contracture of interosseous membrane

Operative

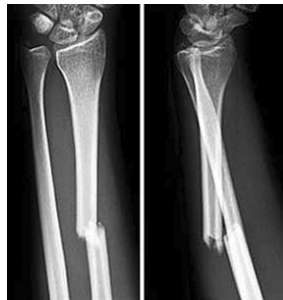1. Indications

- Displaced fractures of both radius and ulna
- Displaced, isolated fracture of either bone
 - Rotated or angulated > 10°
- Fractures combined with radioulnar dislocations
 - Monteggia injury (ulnar fracture and dislocation of radiocapitellar joint)
 - Galeazzi injury (distal radius and dislocation of distal radioulnar joint)
- Open fractures

Monteggia fracture



Galeazzi fracture



2. Goals of operative treatment

- Anatomical reduction
- Restoration of length (ulna and radius)
- Restoration of axial and rotational alignment
- Restoration and stabilization of joints
- Repair of soft-tissue injuries

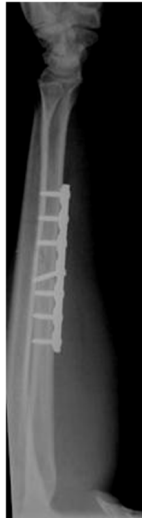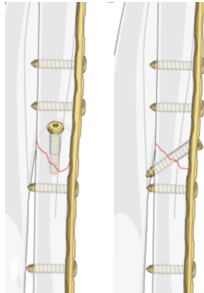
A stable fixation allows immediate postoperative movement.

3. Preoperative planning

- Which approach should be used?
- Which bone will be fixed first?
- What technique will be used: absolute or relative stability?
- Which implants will be used: plates, external fixator or nails can be used?

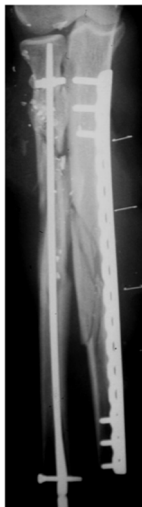4. Technique

- Type A (simple) and B (wedge) fracture
 - Technique with absolute stability
 1. Interfragmentary lag screw (if possible)
 2. Compression plate



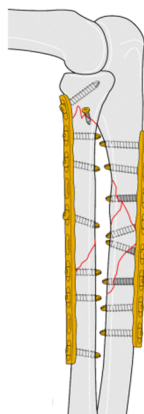
- Type C (complex) fracture
 - Technique with relative stability
 1. Absolute stability technique not often achievable
 2. Relative stability by bridge plating common

Check pronation and supination intraoperatively after reduction and fixation.

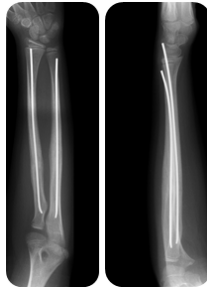

5. Choice of implants

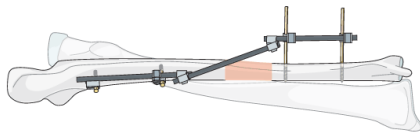
- 3.5 mm plate
 - Gold standard
 - 7–8 holes
 - DCP, LC-DCP, or LCP



- Elastic stable intramedullary nails (ESIN)
 - Remains controversial in adults—no reliable rotation control
 - Excellent results in pediatric forearm diaphyseal fractures



- External fixator
 - Open fractures
 - Careful pin insertion



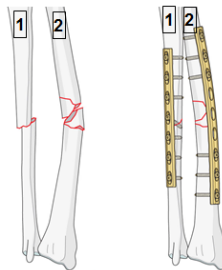
- Fracture consolidation
 1. Cannot be achieved by external fixation alone
 2. Rates of nonunion and malrotation are considerable

Change as soon as plate fixation is safe!

6. Strategy

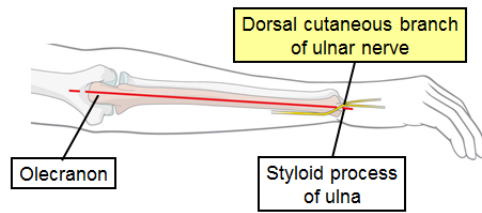
Order of fixation:

- Normally, the simpler of the two fractures will be approached first and preliminary fixation is undertaken.
- If both bones have similar fractures, then the ulna will normally be addressed first.

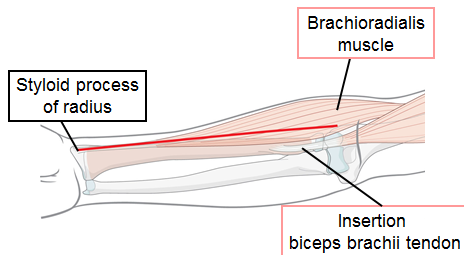


7. Approach

- Ulna
 - Arm is positioned in pronation.
 - Skin incision:
 1. The standard ulnar approach offers good exposure along the whole ulnar shaft. The length of the incision depends on the exposure needed.
 2. The skin incision follows the subcutaneous border of the ulna, along a line drawn between the tip of the olecranon process and the ulnar styloid process.
 3. If the forearm is markedly swollen, it may not be possible to close the skin of the ulnar approach. In these circumstances, it is better to plan the skin incision over the adjacent extensor muscle compartment, so an open incision will have a muscular bed rather than exposing the implant.



- Radius
 - Arm is positioned in supination.
 - Skin incision:
 1. The anterior (Henry) approach offers good exposure of the whole length of the radius. The length of the incision depends on the extent of exposure needed. The Henry approach in the proximal forearm might result in a more obvious scar.
 2. The landmarks for the skin incision are:
 - Styloid process of the radius
 - Groove between the brachioradialis muscle and the insertion of the biceps brachii tendon



8. Postoperative treatment

- Temporary immobilization with a well-padded, bulky splint for 10–14 days is advised to allow adequate soft-tissue healing. This can be longer for unreliable patients. During this period, elevation, gentle finger motion, active and passive, together with elbow flexion/extension and shoulder motion, can be started.
- Functional treatment starts as soon as possible: 6–8 weeks postoperative. There is a high risk of stiffness if this is delayed.
- X-ray control at 1, 6, and 12 weeks postoperatively
- Removal of implants is rarely indicated as there is a high risk of neurovascular injury and refracture.

9. Results and complications

- Excellent to satisfactory 80% to 92%
- Synostosis 2.6% to 6.6%
 - Posttraumatic radioulnar cross union
- Nonunion 3.7% to 10.3%
 - Anatomical reduction and absolute stability crucial
- Refracture after implant removal up to 25%
 - Implant removal is not generally recommended

Summary

You should now be able to:

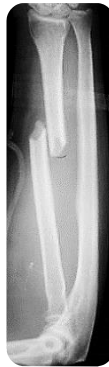- Outline the anatomy and physiology of the forearm
- Outline indications for nonoperative and operative treatment
- Discuss principles of surgical treatment

Questions

What is the correct answer? More answers can be possible.

1. What forearm fracture is this?

- Type A fracture (simple)
- Type B fracture (wedge)
- Type C fracture (complex)



2. Which technique should be applied?

- Relative stability
- Absolute stability
- Adequate stability

3. What is the choice of implant?

- ESIN (Elastic Intramedullary Nail)
- Two lag screws
- Lag screw and protection plate

Reflect on your own practice:

Which content of this lecture will you transfer into your practice?