

Reduction techniques

Rodrigo Pesantez, Myriam Sanchez

Disclaimer

All contents of this study guide are owned by AO Foundation/AO Trauma and cannot be used for any other than private purposes. This work may only be used for your private education.

How to use this handout?

The left column is the information as given during the lecture. The column at the right gives you space to make personal notes.

Learning outcomes

At the end of this lecture you will be able to:

- Define reduction and its types.
- Understand the degrees of displacement of fractures.
- Describe the reduction methods and the tools used.

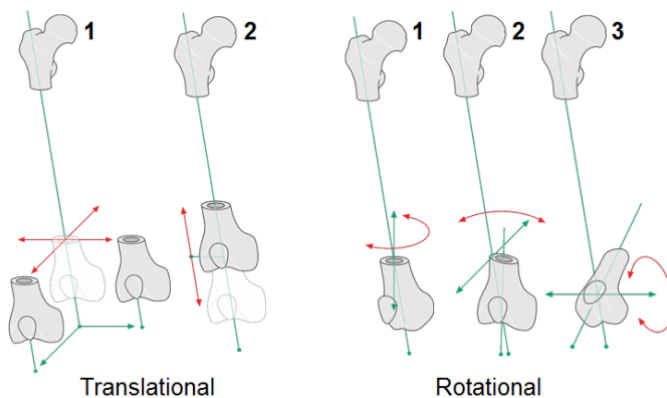
What is reduction?

Reduction is the action of restoring a dislocation or fracture by returning the affected part of the body to its normal position.

Types of displacement

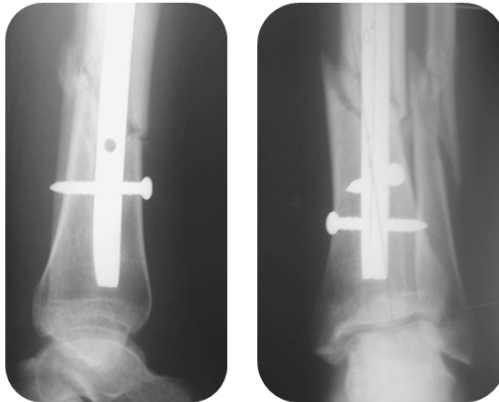
There are two forms of displacement:

1. Translational displacement:
 - Medial or lateral and posterior or anterior
 - Shortening or lengthening
2. Rotational displacement:
 - Internal or external rotational malalignment
 - Valgus or varus malalignment
 - Flexion or extension malalignment



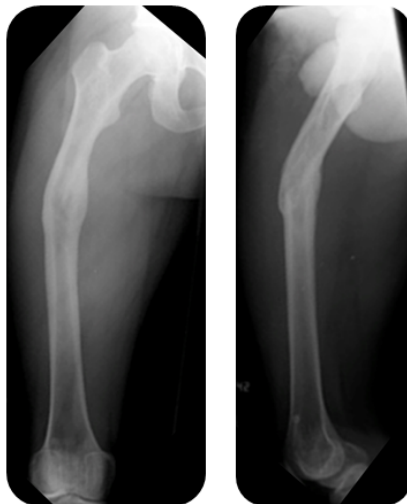
Why fracture reduction?

Example 1



Here we can see a fracture fixed with an intramedullary nail that looks reduced on the lateral view. On the AP view however we can see that there is some valgus angulation of the distal fragment.

Example 2



This fracture was not treated operatively and has healed with varus, antecurvatum, and shortening malunion.

Aim of fracture reduction

Some fractures are reduced perfectly to restore the bony anatomy and others to restore the relationship between the proximal and distal main fragments, setting the scene for recovery of the function of the limb.

Anatomical reduction

- Perfect restoration of bone morphology

Functional reduction

- To restore
 - Length
 - Alignment
 - Rotation

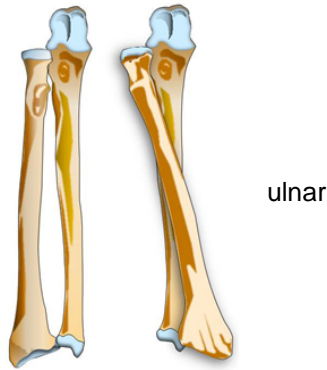
Choice of reduction method

The decision, which reduction method should be used, depends on the location of the fracture:

1. Meta- and diaphyseal fractures usually need functional reduction.
2. Joint fractures need anatomical reduction.

Reduction of diaphyseal fractures

- The functional anatomy is restored (length, alignment, and rotational axis).
- The load-bearing axis of the extremity is restored (especially important in the lower limb).
- An exception is the forearm. The forearm works as a joint (radiohumeral joint, and proximal and distal radiojoints for pronation and supination).



Reduction of articular fractures

- The joint surface is restored anatomically. Gaps and steps in the articular surface must be avoided.
 - “Steps” means that there is a difference between the levels of two main articular fragments.
 - “Gaps” means that there is some space between two adjacent main articular fragments.
- The axial alignment is restored.

Methods

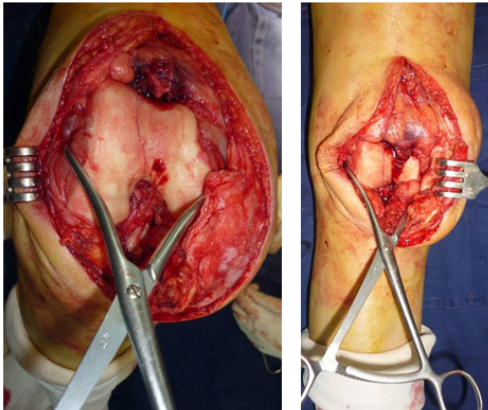
There are two reduction methods:

- Direct reduction where every fragment under direct vision is restored.
- Indirect reduction where the direction is done without direct view on the fracture.

Direct reduction

- **Direct clamp application**

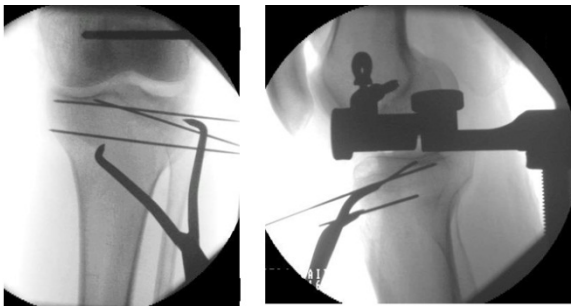
- Joint—The pictures below show how the distal femoral and distal humeral fractures are reduced with a pointed reduction clamp.



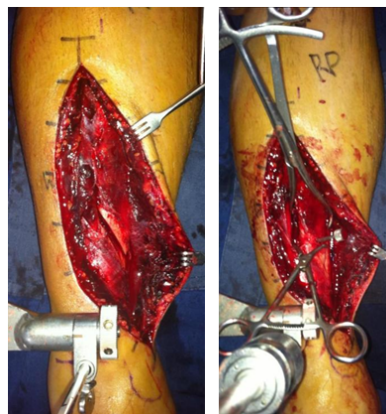Knee

Elbow

- Shaft—De x-rays below show the reduction of a proximal tibia (tibia plateau) using a distractor in combination with a pointed reduction forceps.



On the pictures on the right the distractor is used to gain normal length. The forceps then reduces the main fragments.

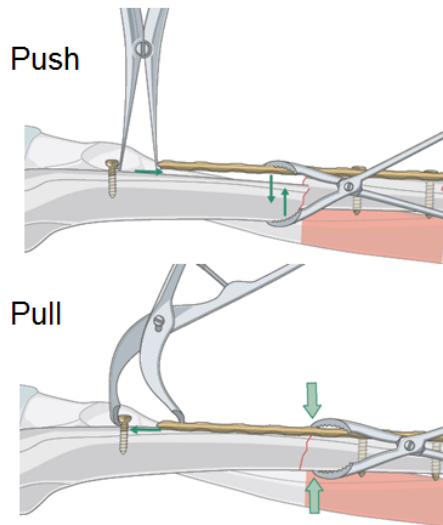


- **Push-pull technique**

In diaphyseal fractures fixed with a plate, the plate is attached to one fragment: then a bone spreader, placed between the end of the plate and an independent screw in one main fragment, can be used to distract the fracture for reduction.

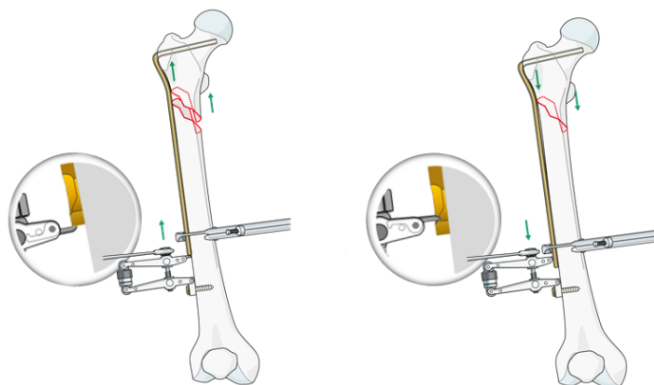
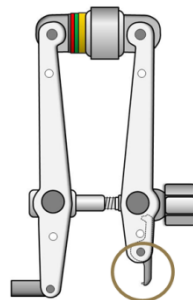
A loosely applied reduction forceps helps to maintain the alignment of the main fragment with the plate.

In a next step, in order to maintain the reduction using the same independent screw, preliminary axial compression can then be obtained by pulling the plate end towards the independent screw with a small Verbrugge clamp.



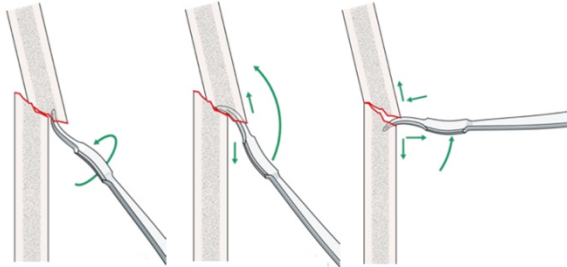
- **Direct application of an implant**

The articulated tension device (ATD) can be used to serve the push-pull principle, as illustrated above. The push stage is achieved by reversing the hook on the articulated tension device.



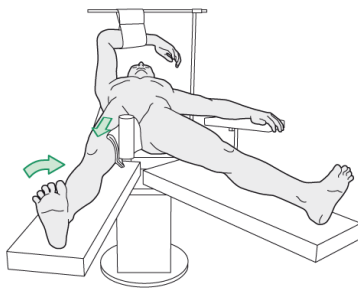
- “Shoehorn technique”

The tip of a Hohmann retractor can be used by placing it between the two bone ends of a fracture. By turning the instrument and levering the fragments into position the fracture can be reduced.



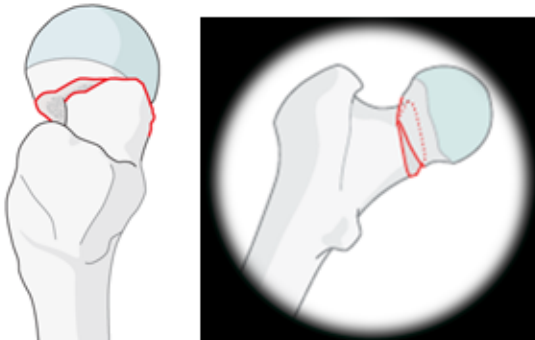
Indirect reduction

- Traction table with image intensifier

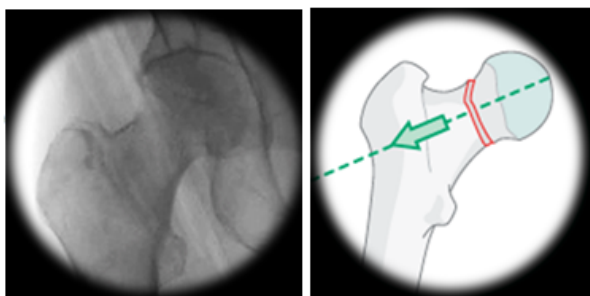


The fracture table is used to facilitate the reduction of certain fractures. It is commonly used for the reduction and fixation of proximal hip fractures.

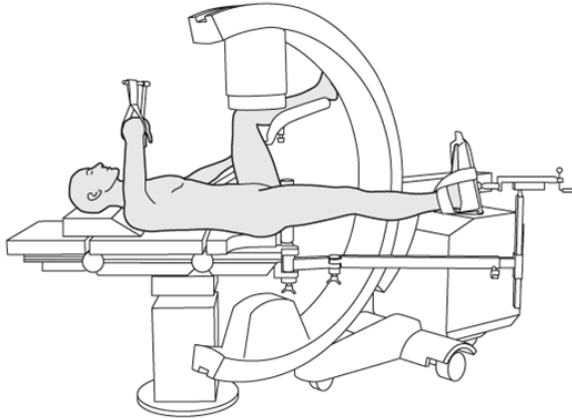
Prereduction



Postreduction

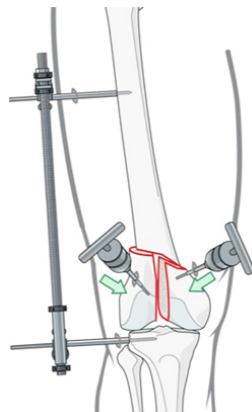


The use of the image intensifier is crucial when performing closed reduction and to guide fixation. When using the extension table, good access with the image intensifier must be possible in both views, AP and lateral view.



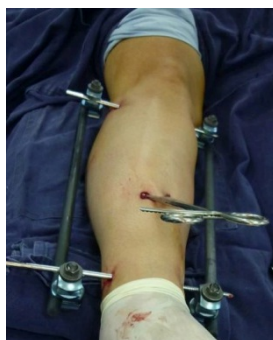- **Distractor and joysticks**

The large distractor is a tool used to distract the fracture. In a next step reduction can be carried out. The distractor can be used with any table, for any type of fracture, and with all kinds of implants, including the intramedullary nail. In combination with joysticks (Schanz screw with T-handle, placed in each fragment) reduction can more easily be obtained.



- **Frames**

Also the external fixator system with frame distraction can be used to obtain preliminary reduction, particularly in length.



Advantages and disadvantages

Direct reduction

- Advantages:
 - Easy to see the fracture
 - Easier to reduce
- Disadvantages:
 - Increases the soft-tissue insult

Indirect reduction

- Advantages:
 - Preserves soft tissues – biology
- Disadvantages:
 - More difficult to reduce
 - More difficult to keep it reduced
 - Increased ionizing radiation

Summary

You should now be able to

- Define reduction and its types.
- Understand the degrees of displacement of fractures.
- Describe the reduction methods and the tools used.

Questions

What is the aim of anatomical reduction?

What are methods of direct reduction/indirect reduction?

- **Direct reduction**

- **Indirect reduction**

The collinear reduction clamp is used for...

- Distraction**
- Compression**
- Distraction and compression**

Reflect on your own practice

Which reduction tools do you have in your hospital?

Which content of this lecture will you transfer into your practice?